

## A GIANT CERVICAL OSTEOCHONDROMA

*Nejmi Kıymaz<sup>1</sup>, Ali Doğan<sup>2</sup>, Nebi Yılmaz<sup>1</sup>, Çiğdem Mumcu<sup>1</sup>*

Yüzüncü Yıl University, Faculty of Medicine, Department of Neurosurgery<sup>1</sup> and  
Orthopedic Surgery<sup>2</sup> Van, Turkey

A giant solitary osteochondroma in 17-year-old-boy was reported. Osteochondromas usually involves the long bones, scapulae, pelvic bones and seldom occurs in the axial skeleton. A 17-year-old boy presented with a swelling at the rear of the neck and an advanced degree of limitation in the movements of his neck. A hard mass sized approximately 7x8 cm was revealed in this region. Cervical x-ray and CT revealed the mass involving the sixth cervical vertebrae. Giant cervical osteochondroma operated and the mass was successfully excised. Osteochondromas that consists the largest portion of benign bone tumors at the spine is seldom. Therefore we are introducing a osteochondroma case located at the lower cervical region where an advance degree of limitation in neck movements that displays no any neurological symptoms and that reaches a very wide mass in size, and which is assumed as unusual.

**Key words:** Cervical spine, osteochondroma, surgical treatment

*Eur J Gen Med 2005; 2(3): 120-122*

### INTRODUCTION

The vertebral localization of the usual bone tumors known as osteochondromas are seldom (1,2). The ratio of osteochondromas in entire bone tumors is nearly 8.5% (3). Osteochondromas can be single, or multiple just like in Hereditary Multiple Exocytoses (HME). In this report we presented a giant osteochondroma located at the lower cervical region.

### CASE

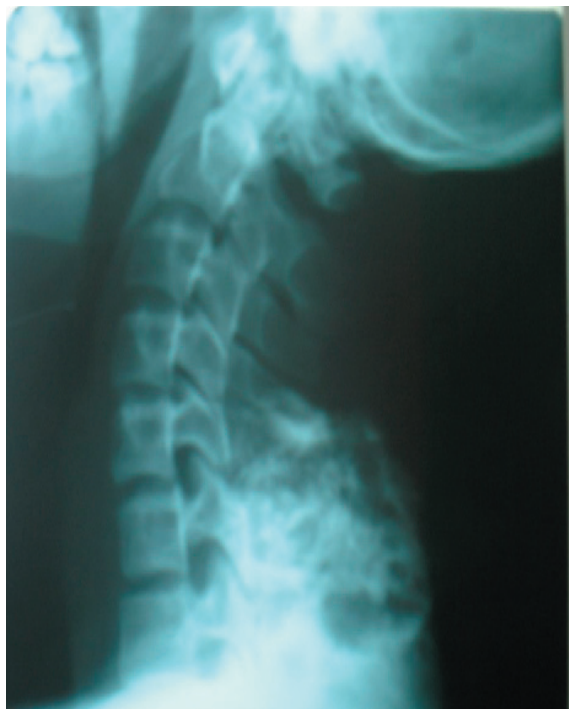The examination of a 17-year-old-boy male patient that was referred to our neurosurgery clinic due to a swelling at the rear of the neck and an advanced degree of limitation in the movements of his neck revealed a hard, palpable mass at the dorsal lower cervical region, sensitive to fixed touches and with a dimension approximately 7x8 cm. The neurological examination of the patient was normal, however the movements of the neck was somehow limited to all directions. Cervical x-ray and cervical computerized tomograms (CT) determined a mass involving

the sixth cervical vertebrae (Figure 1 and 2). Osteochondroma was diagnosed according to radiological findings. The patient was immediately operated and the mass was successfully excised. Histopathological examination also verified the diagnosis of osteochondroma. After surgery the patient's neck movements improved and turned to normal almost in all directions. During a year's follow-up no recurrence was detected.

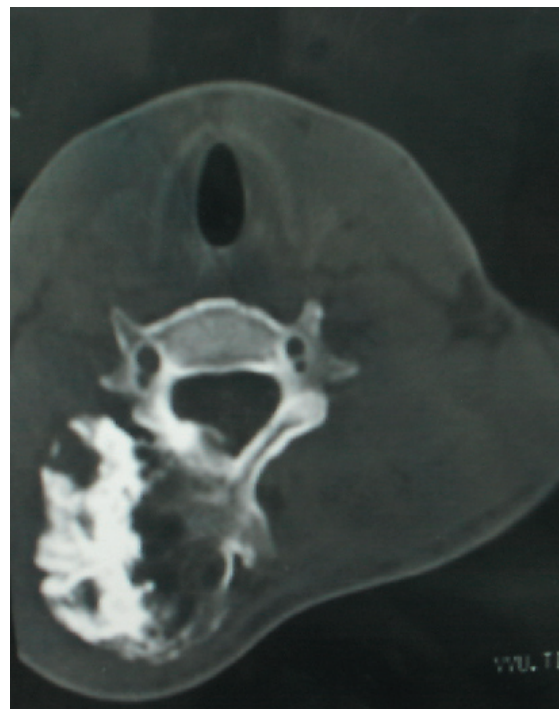
### DISCUSSION

As it is in our case, osteochondromas are more frequent in men and patients are generally under the age of 20 (2,4). Spinal osteochondromas rarely display symptoms. Cervical osteochondromas may compress the vertebral artery, subclavian artery and the common carotis artery (2,5,6). In our case there was no neurological symptom. However, there was an advances degree of limitation in neck movements due to the effect arising from the giant mass of the osteochondroma. After operation the mass was totally extracted and the neck movements of the patient began to

*Correspondence: Dr. Nejmi Kıymaz  
Yuzuncu Yil Universitesi Tip Fakultesi Arastirma  
Hastanesi, Nöroşirürji Kliniği, 65200, Van, Turkey  
Phone: 905324160980, Fax:904322121867  
E-mail: nejmikiymaz@yahoo.co.uk*



**Figure 1. X-Ray of the cervical spine demonstrates the mass related with C6 vertebrae.**



**Figure 2. Axial CT scan through the lamina of C6 vertebra demonstrates an osseous outgrowth on the right side.**

improve.

The main method that must be selected for diagnosis is x-ray and CT. The cartilaginous and bone components of the tumor can be determined by CT and its relationship with the peripheral region and neural tissues can be also determined (2,7,8). Magnetic resonance imaging is also helpful for the demonstration of spinal cord or nerve root compression (8). Pathologically, osteochondromas represent a dysplastic-hyperplastic disturbance of bone from progressive enchondral ossification (8,9). Our histologic diagnosis was osteochondroma.

According to the localization of osteochondromas different standard surgical techniques can be applied. The purpose of surgical intervention should be to totally remove the tumor (1,10). In the present case the mass was extracted in total.

Osteochondromas that consists the largest portion of benign bone tumors, seldomly affects the spine. Therefore we presented a osteochondroma locate in the lower cervical region with advanced limitation in neck movements and without any neurological symptom. This unusual presentation was considered clinically important so presented here.

#### REFERENCES

1. Oga M, Nakatani F, Ikuta K, Tamaru T, Arima J, Tomishige M. Treatment of cervical cord compression, caused by hereditary multiple exostosis, with laminoplasty: A case report. *Spine* 2000;25:1290-2
2. Arasil E, Erdem A, Yuceer N. Osteochondroma of the upper cervical spine: A case report. *Spine* 1996;21:516-8
3. Dahlin DC, Unni KK. *Bone Tumors: General Aspects and Data on 8542 Cases*. 4<sup>th</sup> ed. Springfield, IL: Charles C Thomas 1986;19:228-9
4. Ratliff J, Voorhies R. Osteochondroma of the C5 lamina with cord compression: Case report and review of the literature. *Spine* 2000;25:1293-5
5. Resnick D, Kyriakos M, Greenway GD. *Bone and Joint Imaging*. Saunders, Philadelphia 1989
6. Woertler K, Lindner N, Gosheger G, Brinkschmidt C, Heindel W. Osteochondroma: MR imaging of tumor-related complications. *Eur Radiol* 2000;10:832-40
7. Cooke RS, Cumming WJ, Cowie RA. Osteochondroma of the cervical spine: Case report and review of the literature. *Br J Neurosurg* 1994;8:359-63

8. Cirak B, Karabulut N, Palaoglu S. Cervical osteochondroma as a cause of spinal cord compression in a patient with hereditary multiple exostoses: Computed tomography and magnetic resonance imaging findings. *Australas Radiol* 2002;46:309-11
9. Khosla A, Martin DS, Awwad EE. The solitary intraspinal vertebral osteochondroma. An unusual cause of compressive myelopathy features and literature review. *Spine* 1999;24:77-81
10. Morard M, de Preux J. Solitary osteochondroma presenting as a neck mass with spinal cord compression syndrome. *Surg Neurol*. 1992;37:402-5