

A New and Simple Silicone Intubation Method for Dacryocystorhinostomy

Meral Yıldız, Bülent Yazıcı, Berna Akova, Ali Karataş

Uludag University, Medical Faculty, Department of Ophthalmology, Bursa, Turkey

Eur J Gen Med 2011;8(1):36-9

Received: 08.08.2010

Accepted: 10.08.2010

ABSTRACT

Aim: To describe a new and simple bicanalicular silicone intubation technique, which can be used during dacryocystorhinostomy (DCR) surgery.

Method: In this method, a lacrimal canula is used to pass the silicone tube through the lacrimal canaliculi. A 26-Gauge curved lacrimal canula is inserted into one end of a silicone tube with an inner diameter of 0.50 mm and outer diameter of 0.94 mm. The lacrimal puncta are enlarged using a one-snip procedure. The canula is introduced together with the tube into the punctum and advanced to the rhinostomy site. Here, the tube is detached from the canula by a forceps and the canula retracted. The other canaliculus is intubated in a similar manner. The tubes are passed out through the rhinostomy site and nose, and tied inside the nose.

Result: Silicone intubation was performed in 32 DCR procedures in 30 patients (revision DCR in 13 eyes, primary DCR in 10 eyes, canalicular DCR in 7 eyes, and endonasal DCR in 2 eyes) using the described method. No significant difficulty was encountered in any case. During the follow-up, a slit punctum developed in 1 eye and prolapsus of the tube at the medial canthus in another eye; no other complication was observed.

Conclusion: This method eliminates the need for retrieval of a metal leader from the lacrimal canaliculi and rhinostomy site and facilitates silicone intubation during DCR. It is a relatively nontraumatic and inexpensive method that may be an alternative to the other intubation methods.

Key words: Dacryocystorhinostomy, lacrimal canula, silicone intubation.

Correspondence: Meral Yıldız,
Uludag University Faculty of Medicine
Department of Ophthalmology
Gorukle, Bursa, 16059 Turkey
Tel: 902242952447, Fax: 902244428070
E-mail: meraly@uludag.edu.tr

Dakryosistorinostomide Yeni ve Basit Silikon Entübasyon Metodu

Amaç: Dakryosistorinostomi (DSR) cerrahisi sırasında kullanılabilir yeni ve basit bir bikanaliküler silikon entübasyon tekniğini tanımlamak.

Metod: Bu metotta bir lakrimal kanül lakrimal kanalikül boyunca silikon tüpü geçirmek için kullanıldı. 26 gauge eğimli bir lakrimal kanül iç çapı 0.50 mm ve dış çapı 0.94 mm olan silikon bit tübün bir ucuna geçirildi. Lakrimal punktumlar tekli snip işlemi uygulanarak genişletildi. Kanül tüple birlikte punktuma sokuldu ve rinostomi bölgesine ilerletildi. Burada, tüp bir forseps yardımıyla kanülden ayrıldı ve kanül geri çekildi. Diğer kanalikül benzer yöntemle entübe edildi. Tüpler rinostomi bölgesinden burun içine geçirildi ve burun içinde bağlandı.

Bulgular: Silikon entübasyon tanımlanan metod kullanılarak 30 hastanın 32 DSR prosedüründe kullanıldı (13 göz revizyon DSR, 10 göz primer DSR, 7 göz kanaliküler DSR ve 2 göz endonazal DSR). Hiçbir olguda ciddi bir zorlukla karşılaşılmadı. İzlem sırasında, bir gözde yarık punktum ve başka bir gözde iç kantüste tüp prolapsusu gelişti; başka bir komplikasyon gözlenmedi.

Sonuç: Bu metod rinostomi bölgesi ve lakrimal kanalikülden metal bir kılavuzun geçirilme gereksinimini giderdi ve DSR sırasında silikon entübasyonu kolaylaştırdı. Görece olarak, travmatik ve pahalı olmayan bu metod, diğer entübasyon metodlarına alternatif olabilir.

Anahtar kelimeler: Dacryocystorhinostomy-lacrimal canula-silicone intubation

INTRODUCTION

Bicanalicular silicone tube placement is a widely used method in both external and endonasal dacryocystorhinostomy (DCR) surgeries. It aims to maintain canalicular or anastomotic patency during the healing period and may improve surgical results when used appropriately (1,2). Prepackaged sets consisting of silicone tubes attached to metal probes are commonly used for silicone intubation (3,4). The disadvantages associated with this device is that it is expensive; it is difficult to retrieve the long metal probes from the rhinostomy site; and the procedure may be traumatic. In this report, we present an easier and economical nasolacrimal intubation method in which the silicone tube is passed from the canaliculi over the tip of a lacrimal canula.

MATERIALS AND METHODS

In this method, silicone tubes with an inner diameter of 0.50 mm and outer diameter of 0.94 mm are used (NG5941 2A, Bausch&Lomb Surgical, Heidelberg, Germany). A 15-m long nonsterile tube is cut into approximately 20-cm segments and sterilized with ethylene oxide. The silicone tube is placed before uniting anterior nasal and lacrimal flaps during surgery. Superior and inferior puncti are enlarged with a single vertical incision ("one snip"). To pass the silicone tube through the canaliculi, a 35-mm long, 26-Gauge curved lacrimal canula (M 9276, Sterimedix Ltd, Worcestershire, England) is used (Figure 1). The canula is inserted into the silicone tube at one end and advanced approximately 2 to 3 mm. The lacrimal canula with the silicone tube

at one end is then introduced into the upper punctum and advanced through the superior canaliculus (Figure 2). When the canula and the tube appear inside the sac, the tube is detached from the canula by a forceps and pulled out (Figure 3). Then the canula is retracted. The canula is inserted into the tube at the other end and passed through the inferior canaliculus in an identical procedure. Both ends of the silicone tube are gripped at the rhinostomy site with the curved hemostat advanced upwards in the nasal cavity and pulled out of the nose. The ends of the silicone tube are tied with several knots and after cutting the excess, the remaining part is left to be retracted. The knot should not be retracted up to the rhinostomy site nor should it protrude from the nostril. It should remain approximately 10 mm inside the nostril. In children, it may be useful to fixate the tube to the lateral nasal wall with an absorbable suture to prevent the prolapsus at the medial canthus.

RESULTS

Between December 2001 and January 2004, using the aforementioned method, we placed the silicone tube in 30 patients (8 women and 24 men; mean age: 47.5 years; age range: 2 to 79 years) during 32 DCR surgeries. The intubation was performed at the time of revision DCR, primary DCR, canalicular DCR, and endonasal DCR in 13, 10, 7, and 2 eyes, respectively. We did not encounter any difficulty related with the technique in any case, and did not need to convert to another method. The silicone tubes were removed after surgery after a mean period of 1.8 months (range, 1 week to 4 months).

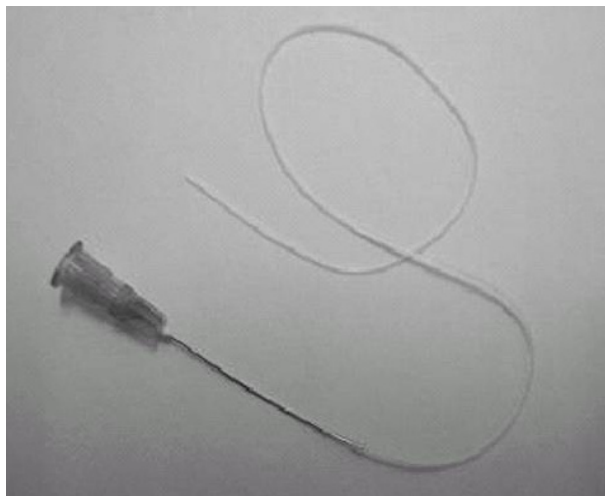


Figure 1. Silicone tube approximately 20 cm in length is threaded onto a 26-Gauge lacrimal irrigation canula.

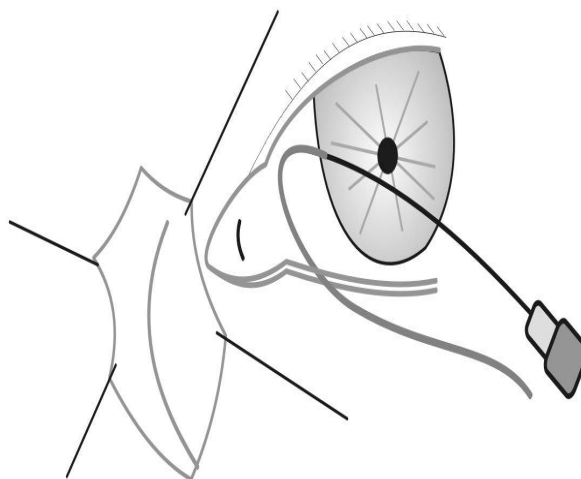


Figure 2. Insertion of the canula together with the silicone tube into the superior canaliculus.

Mean follow-up was 4.7 months after surgery (range, 2 to 17 months). During the follow-up period, slit punctum developed in one eye of a child and the silicone tube extruded at the medial canthus in another eye. No other complication was noted.

DISCUSSION

Silicone intubation simultaneous with DCR was first described by Gibbs (5). Silicone tube is placed almost routinely during endonasal DCR (6). On the other hand, routine use of silicone tubes at the time of external DCR is controversial (7,8).

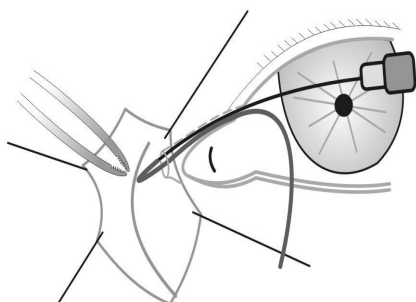


Figure 3. Detachment of the silicone tube from the canula inside the lacrimal sac.

Silicone intubation is generally indicated for canalicular obstruction and the conditions in which excessive postoperative scarring might occur. Various sets and methods have been described for lacrimal intubation (9-11). The O'Donogh intubation set in Europe, (12,13) and Quickert (9) or Crawford (11) sets in the United States are the most commonly preferred. In these sets, silicone tubes are attached to metal probes ranging in length from 45 mm to 177 mm. In this method, the metal probe passes from the canaliculi first and the silicone tube follows it. To place the tube, it is necessary to pass the whole probe from the canalicular segment and to retrieve it from the rhinostomy site. Uneasy manipulation of the metal probes, the difficulty in retrieving the probe from the wound and the nose, possible canalicular trauma, and relative expense are the main disadvantages of this method. Although curved and shorter metal probes are proposed, the difficulties in retrieving the probes have not yet been overcome (14,15). Archer and Hurwitz (16) have suggested a different intubation method for external DCR surgery. In this method, a lacrimal probe (Bowman No. 1 probe, 0.90 mm in diameter) is used for passing the tubes through the canaliculus. The outer diameter of the silicone tubes is 0.94 mm. Oblique incisions are made 3 mm away from the ends of the tubes. The lacrimal probe is inserted into this incision and advanced about 2 mm. The probe with the tube is inserted into the punctum, advanced through the can-

aliculus, and pulled out from the cavity of the sac. The disadvantages of this technique include the difficulty in adjusting the length of vertical incision on the tube, inserting the metal probe into the incision, and breaking of the fragile part at the end of the tube. In addition, it may be difficult to pass the lacrimal probe attached to the silicone tube through the relatively narrower canaliculus. In our technique, the silicone tube is advanced in front of an introducer, i.e. a lacrimal canula. The canula that we used was 0.45 mm in diameter. It can be easily inserted into the silicone tube, and forms a relatively tight connection. Enlargement of the lacrimal punctum with one snip facilitates both the entrance of the silicone tube and postoperative lacrimal irrigation. During lacrimal intubation, the metal probes may easily cause canicular injury. To avoid this complication, the tubes should be advanced gently according to the trace of the canaliculus. Nasolacrimal canal obstruction may induce marked changes in the anatomical course of the common canaliculus particularly in patients with the enlarged lacrimal sacs (17). The curved and light lacrimal canula easily accords the trace of the canaliculi and does not lead to any distortion. In our opinion, straight and heavier metal probes are more likely to cause canicular distortion.

Another advantage of the method described herein is that it is relatively inexpensive. Silicone tubes, cut into 20-cm-long segments, regardless of the sterilization expenses, cost approximately US \$3 for each segment. The prices of the prepackaged intubation sets sold in Turkey range between US \$35 and \$100. Lacrimal canulas may be resterilized under ethylene oxide and reused.

This report essentially aims to present a surgical technique. To compare this technique with the traditional silicone intubation techniques may provide further information. The method presented here may be easily used in endonasal DCR surgery as well as external DCR. The advancement of the lacrimal canula as far as possible through the nose facilitates the gripping and pulling out of the tube.

REFERENCES

1. Tarbet KJ, Custer PL. External dacryocystorhinostomy: surgical success, patient satisfaction, and economic cost. *Ophthalmology* 1995;102:1065-70.
2. Older JJ. Routine use of a silicone stent in a dacryocystorhinostomy. *Ophthalmic Surg* 1982;13:911-5.
3. Levine MR. Dacryocystorhinostomy. In: Levine MR, ed. *Manual of Oculoplastic Surgery*. Boston, Mass: Butterworth-Heinemann; 1996:37-45.
4. Sires BS, Lemke BN. Dacryocystorhinostomy. In: Albert DM, ed. *Ophthalmic Surgery: Principles and Techniques*. Blackwell Science: Boston; 1999. Vol II, pp:1403-18.
5. Gibbs DC. New probe for the intubation of lacrimal canaliculi with silicone rubber tubing. *Br J Ophthalmol* 1967;51:198.
6. Woog JJ, Kennedy RH, Custer PL, Kaltreider SA, Meyer DR, Camara JG. Endonasal dacryocystorhinostomy: a report by the American Academy of Ophthalmology. *Ophthalmology* 2001;108:2369-77.
7. Allen K, Berlin AJ. Dacryocystorhinostomy failure: association with nasolacrimal silicone intubation. *Ophthalmic Surg* 1989;20:486-9.
8. Rosen N, Sharir M, Moverman DC, Rosner M. Dacryocystorhinostomy with silicone tubes: evaluation of 253 cases. *Ophthalmic Surg* 1989;20:115-119.
9. Quickert MH, Dryden RM. Probes for intubation in lacrimal drainage. *Trans Am Acad Ophthalmol Otolaryngol* 1970;74:431-433.
10. Guibor P. Canaliculus intubation set. *Trans Am Acad Ophthalmol Otolaryngol* 1975;79:419-420.
11. Crawford JS. Intubation of obstructions in the lacrimal system. *Can J Ophthalmol* 1977;12:289-292.
12. Hopkisson B, Suharwardy J. Sleeves for fixation of silastic nasolacrimal tubes. *Br J Ophthalmol* 1995;79:664-666.
13. Malhotra R, Wright M, Olver JJ. A consideration of time taken to do dacryocystorhinostomy surgery. *Eye* 2003;17:691-696.
14. Bodian M. A "miniprobe" for use in dacryocystorhinostomy surgery. *Ophthalmology* 1980;87:713-715.
15. Bartley GB. Lacrimal intubation during dacryocystorhinostomy. *Am J Ophthalmol* 1988;106:635.
16. Archer KF, Hurwitz JJ. An alternative method of canicular stent tube placement in lacrimal drainage surgery. *Ophthalmic Surg* 1988;19:510-514.
17. Yazıcı B, Yazıcı Z. Anatomical position of the common canaliculus in patients with large lacrimal sac. *Ophthalm Plast Reconstr Surg* 2008;24:90-3.