



Abdominal Aorta and Its Branches: Morphometry - Variations In Autopsy Cases

Ahmet Songür¹, Muhsin Toktaş¹, Ozan Alkoç¹, Tolgahan Acar¹, İbrahim Uzun², Orhan Baş³, Oğuz Aslan Özen⁴

¹Kocatepe University, School of Medicine, Department of Anatomy, Afyonkarahisar.

²Council of Forensic Medicine, Istanbul.

³Rize University, School of Medicine, Department of Anatomy, Rize.

⁴Namık Kemal University School of Medicine, Department of Anatomy, Tekirdag, Turkey

Eur J Gen Med 2010;7(3):321-325

Received: 07.01.2010

Accepted: 05.04.2010

ABSTRACT

Aim: Knowing the morphology of abdominal aorta (AA) and its branches are important as regards to diagnosis and surgical treatment. The aims of this study were to a) make morphometric measurements of AA and its branches, b) to investigate sites of the origins of the branches and their relationships and variations, and c) to compare the results with literature.

Method: Ninety-five AA which had been removed in autopsies were measured with caliper morphometrically to determine diameters of branches and distances between branches. Possible variation of the vessels were investigated and photographed.

Result: It was found that diameters of celiac trunk (CT), superior mesenteric artery (SMA) and inferior mesenteric artery (IMA) were 6.43 ± 1.59 mm, 7.38 ± 1.67 mm and 3.61 ± 0.72 mm respectively. The distances between CT and aortic bifurcation (AB), CT and SMA, SMA and IMA, IMA and AB were 107.21 ± 11.46 mm, 14.34 ± 2.67 mm, 57.76 ± 8.04 mm, 35.20 ± 7.41 mm respectively. Numerous variations were observed during the study. These variations involved inferior phrenic artery (single trunk arising from CT, 4.2%), renal artery-RA (duplicated right RA 9.5%, duplicated left RA 4.2%, bilaterally duplicated 3.1%, %16.8 total multiple RA), gonadal arteries-GA (single GA, 1%), lumbar arteries-LA (3 pairs of LA 11.5%, 3rd or 4th LA arising as single trunk 3.1%) and median sacral artery (agenesis 2.1%).

Conclusion: Knowledge of morphology of AA and its branches is important in regards to the diagnosis, surgical treatment and endovascular interventions of these vessels. We think our study will contribute to the medical education and clinical medicine in our country.

Key words: Abdominal aorta, branches, variation, morphometry

Correspondence: Dr. Ahmet Songur
Afyon Kocatepe University School of
Medicine, Department of Anatomy. 03100,
Afyonkarahisar, Turkey
Phone: 902722171753
E-mail: asongur55@yahoo.com

Aorta Abdominalis ve Dallari: Otopsi Olgularında Morfometri ve Varyasyonları

Amaç: Abdominal aorta ve dallarının morfolojisini bilmek tanı ve cerrahi tedavi açısından önemlidir. Bu çalışmanın amacı a) Aorta abdominalis (AA) ve dallarının morфометrik ölçümlerini yapmak b) Dalların köken aldığı yerleri, ilişkilerini ve varyasyonlarını araştırmak c) Sonuçları literatürle karşılaştırmaktır.

Metod: Otopsielerde çıkarılan 95 AA, dalların çaplarını ve dallar arasındaki mesafeyi belirlemek amacıyla kumpas ile morфометrik olarak ölçüldü. Olası damar varyasyonları incelendi ve fotoğraflandı.

Bulgular: Truncus coeliacus (TC), a. mesenterica superior (AMS) ve a. mesenterica inferior'un (AMI) çapları sırasıyla 6.43 ± 1.59 mm, 7.38 ± 1.67 mm ve 3.61 ± 0.72 mm olarak bulundu. TC ile bifurcatio aortae (BA), TC ile AMS, AMS ile AMI, AMI ile BA arası mesafeler sırasıyla 107.21 ± 11.46 mm, 14.34 ± 2.67 mm, 57.76 ± 8.04 mm, 35.20 ± 7.41 mm olarak bulundu. Çalışma sırasında çok sayıda varyasyon gözlemlendi. Bu varyasyonlar a. phrenica inferior (TC'den tek kök olarak çıkması, %4.2), a. renalis (AR) (sağda çift AR %9.5, solda çift AR %4.2, bilateral çift AR %3.1, toplam çift AR %16.8), a. gonadalis (tek AG %1), a. lumbalis (3 çift AL %11.5, 3. veya 4. AL nin tek kök olarak çıkması %3.1) ve a. sacralis mediana (agenesis %2.1) ile ilgili idi.

Sonuç: Abdominal aorta ve dallarının morfolojisini bilmek tanı, cerrahi tedavi ve bu damarlarla ilgili endovasküler girişimler açısından önemlidir. Çalışmamızın ülkemizdeki tıp eğitimine ve klinik bilimlere katkısı olacağına inanıyoruz.

Anahtar kelimeler: Aorta abdominalis, dallar, varyasyon, morфомetri.

INTRODUCTION

The abdominal aorta (AA) begins at aortic hiatus of the diaphragm, anterior to the inferior border of the 12th thoracic vertebra and the thoracolumbar intervertebral disc. It descends anterior to the lumbar vertebrae to end at the lower border of the 4th lumbar vertebra, slightly to the left of the midline, by dividing into two common iliac arteries. It diminishes in calibre from above downward, giving off its branches. The branches of AA are grouped into anterior, lateral and dorsal branches. The anterior and lateral branches are distributed to the viscera. The dorsal branches supply blood to the body wall, vertebral column, vertebral canal and its contents (1,2). The celiac trunk (CT) is the first anterior branch of AA and it arises from the AA immediately below the aortic hiatus at the level of T12-L1 vertebra. It is c. 1.5-2 cm long. Superior mesenteric artery (SMA) originates c. 1 cm below the CT, at the level of the L1-L2 intervertebral disc. The inferior mesenteric artery (IMA) arises from the anterior or left anterolateral aspect of the AA at the level of L3 and 3-4 cm above aortic bifurcation (AB). Inferior phrenic arteries (IPA) arise just above the CT. The left and right middle suprarenal arteries (MSRA) arise from the lateral aspect of AA, level with the SMA. The left and right renal arteries (RA) originate just below SMA and the right arises slightly higher than the left. Gonadal arteries (GA) arise inferior to the RA. Lumbar arteries (LA) arise from the posterolateral aspect of AA and there are usually 4 pairs. Median sacral artery (MSA) is a small branch that arises from the posterior aspect of the aorta a little above its bifurcation (1,3). Variations in AA and its branches are frequently observed and they occur due to embryological developmen-

tal changes (4-6). For example IPA and CT may originate from AA as a single common trunk or a fifth pair of LA may occasionally arise from the MSA (1).

Knowledge of morphology of AA and its branches is important in regards to renal transplantation, renal trauma surgery, radiological imaging and surgical treatment of aortic aneurysms (7,8). Variations of GA should be noted while performing surgical and radiological procedures on kidneys (4). IPA is the most common source of extrahepatic collateral blood supply for hepatocellular carcinoma (HCC) and frequently supplies HCCs located in the bare area of the liver. Therefore anatomy of IPA should be known for surgical treatment of this tumor (9). Knowledge of the anatomical variations of LA is important for surgical operations involving the retroperitoneal region (10). The aim of this study was to a) make morphometric measurements of AA and its branches, b) to investigate sites of the origins of the branches and their relationships and variations, and c) to compare the results with literature.

MATERIALS AND METHODS

Our study was performed on 95 AA specimens which were obtained from Specialized Committee of Morgue at Council of Forensic Medicine by their permission. Measurements were done in Afyon Kocatepe University, School of Medicine, Department of Anatomy in 2007. Specimens of AA and its branches which had been removed in autopsies were measured with analog caliper morphometrically to determine diameters of branches (CT, SMA and IMA) and distances between branches (CT-AB, CT-SMA, SMA-IMA and IMA-AB). Results were shown

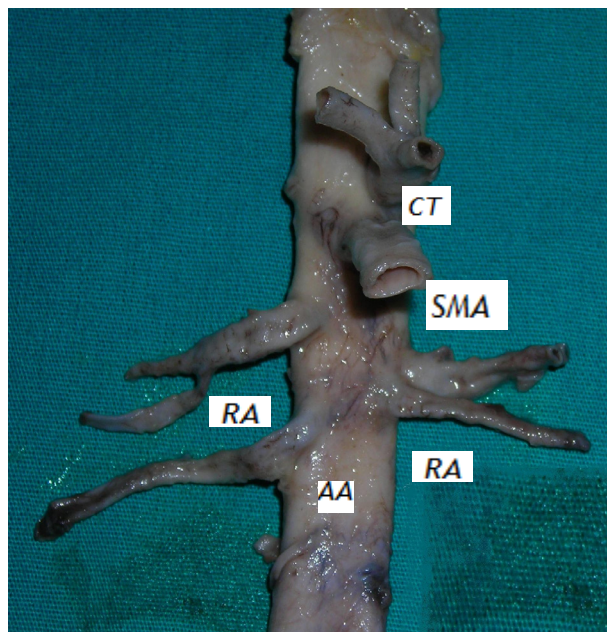


Figure 1. Bilateral double renal artery (RA).

AA: Abdominal aorta, CT: Celiac trunk, RA: Renal artery, SMA: Superior mesenteric artery

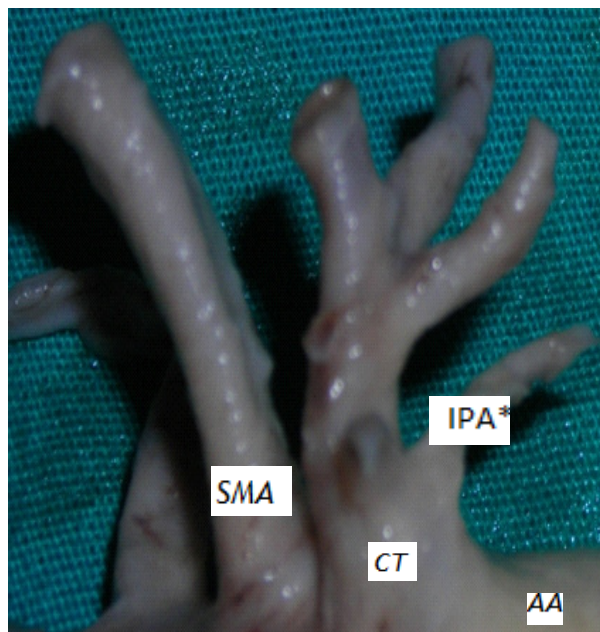


Figure 2. Inferior phrenic artery (IPA) arising as a single trunk from celiac trunk (CT).

AA: Abdominal aorta, CT: Celiac trunk, IPA: Inferior phrenic artery, SMA: Superior mesenteric artery

as mean±standard deviation. The demographic characteristics of the cases (sex, age, height and weight) and any encountered variations and anomalies were recorded during the macroscopical observations. Great care was taken not to change the course of arteries. The structures of the AA and variations were photographed using a digital camera (Canon Power-Shot G5, Japan).

RESULTS

Demographic results; 66 (69.47%) of the bodies from which the specimens were taken were males, 29 (30.53%) of them were females. Mean age was 38.83±18.29 years (males 37.17±17.69, females 42.62±20.64), mean height was 166.12±10.32 cm (males 169.14±9.41, females 159.24±9.02), mean weight was 67.53±16.72 kg (males 71.08±16.61, females 59.45±14.14). There was a statistically significant difference between height (0.000) and weight (0.001) of males and females.

Morphometric results; a- Diameter measurements: The diameters of CT, SMA and IMA were found to be 6.43±1.59 mm, 7.38±1.67 mm, 3.61±0.72 mm, respectively. **b- Distance measurements:** Distances between

CT-AB, CT-SMA, SMA-IMA and IAM-AB were measured as 107.21±11.46 mm, 14.34±2.67 mm, 57.76±8.04 mm, 35.20±7.41 mm, respectively. There was no statistically significant difference between sexes in regards to diameter and distance values.

Variations: Numerous variations were observed during the study. These variations involved IPA (single trunk arising from CT, 4.2%), RA (duplicated right RA 9.5%, duplicated left RA 4.2%, bilaterally duplicated 3.1%, %16.8 total multiple RA), GA (single GA 1%), LA (3 pairs of LA 11.5%, 3rd or 4th LA arising as single trunk 3.1%) and MSA (agenesis 2.1%).

DISCUSSION

We think that the demographic information of the cadavers from which the specimens were taken is consistent with the demographic data of adults in our country. Therefore, we think that the results obtained from AA and its branches can be considered as data belonging to the average individuals. The diameter of CT was found to be 7±0.6 mm in a study of 21 cadavers (11). It was determined as 8 mm in another series (12). We found it as

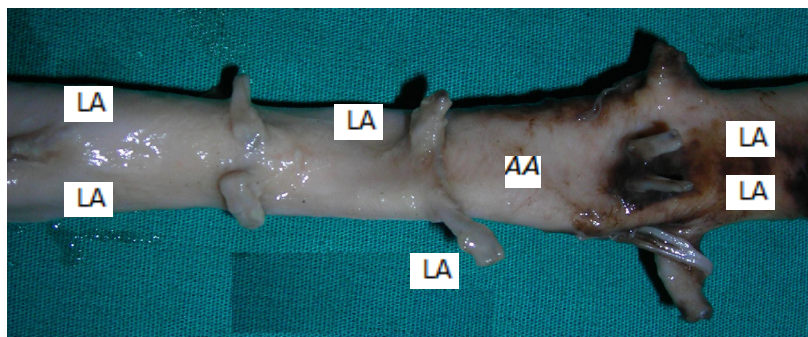


Figure 3. 3 pairs of lumbar arteries (LA). AA: Abdominal aorta, LA: Lumbar artery

6.61±1.67 mm in our series. SMA diameter was observed as 6.6 mm in a case report in literature (13). We found it as 7.38±1.67 mm in our study. Our findings are similar to those in literature.

Variations of the branches of AA and their relations to surrounding structures are important in regards to intra-abdominal surgery. Many variations of these vessels have been reported in the literature. The arteries that show frequent variations include CT, RA and GA (4). Deepthinath et al. reported variations in an adult cadaver which were double RA, double GA, MSRA and IPA that branched from the CT on the left side. The IPA and MSRA arose from the right RA on the right side (4).

In a study by Saldarriaga et al. conducted on 196 cadavers multiple RA were observed in 22.3% of the specimens and also double RA were more frequently observed on the left side (14). We found multiple RA rate to be lower (16.8%) and double RA were more frequently observed on the right side. Our findings were different from those of Saldarriaga et al.

Cavdar et al. reported a case of left IPA and left gastric artery arising from the long CT via a common trunk (5). In a series of 330 cadavers, Loukas et al. determined that right and left IPA originated from CT in 40% and 47% of the specimens, respectively (15). We observed in our series that IPA arose from CT as a common trunk in 3 cases (3.1%).

In one of these 3 cases, right IPA was observed to have originated from CT unilaterally. The other 2 cases were bilateral. However, one of the latter 2 cases was considered to be doubtful since the origins of IPAs could not have been identified depending on improper dissection technique. Also our finding can be controversial due to the technique used for obtaining the specimens. Basar

et al. reported a case of CT agenesis detected in angiography (16). We did not encounter any CT agenesis in our series. Demirtas et al. reported a rare variation of the branching of the CT (17). There are many studies on CT anomalies found in literature. This clearly indicates that CT anomalies should be taken into consideration during intra-abdominal operations and radiological investigations.

In an anatomical study of 102 cases by Baniel et al., it was determined that the number of LA ranged between 2 and 4 and also there were 3 pairs in 60% of the cases (10). We found in our series that there were 3 pairs of LA in 11.5% of the cases and 3rd or 4th pair of LA arose as a single trunk in 3 cases (3.1%).

Ozan et al. examined 30 adult abdominal aorta specimens dissected from cadavers and determined the CT-SMA distance as 17.9 mm (7). Our value (14.34±4.37 mm) is close to this. Yahel et al. examined 42 descending aorta and analyzed morphometrically by dividing it into segments. They found CT-SMA distance as 16±4.0 mm (6). Khamanarong et al. found total double RA rate as 17% (18). Our value, which is 16.8%, is consistent with the literature. Bordei et al. examined 54 cases of double RA and determined that 6 of them were bilateral (11.6%) (8). We found that 2 of the 8 double RA case were bilateral (25%). This value is higher than that of Bordei et al.

It is important to know the morphology of AA and its branches with regards to the diagnosis, surgical treatment and endovascular interventions related to it. We think our study will contribute to clinical medicine and demographics of our country

REFERENCES

1. Borley NR (ed.) *Posterior abdominal wall and retroperitoneum*. In: *Gray's Anatomy*. 39th ed. Edinburgh: Churchill Livingstone; 2005. p. 1116-9
2. Moore KL, Dalley AF. *Clinically Oriented Anatomy*. 4th ed. Baltimore: Lippincott Williams & Wilkins; 1999.
3. Snell RS. *Clinical Anatomy for Medical Students*. 7th ed. Lippincott Williams & Wilkins; 2003
4. Deepthinath R, Sathesha Nayak B, Mehta RB et al. Multiple variations in the paired arteries of the abdominal aorta. *Clin Anat* 2006;19: 566-8.
5. Cavdar S, Gurbuz J, Zeybek A, Sehirli U, Abik L, Ozdogmus O. A variation of coeliac trunk. *Kaibogaku Zasshi* 1998;73: 505-8.
6. Yahel J, Arensburg B. The topographic relationships of the unpaired visceral branches of the aorta. *Clin Anat* 1998;11: 304-9
7. Ozan H, Alemdaroglu A, Sinav A, Gümüşalan Y. Location of the ostia of the renal arteries in the aorta. *Surg Radiol Anat* 1997;19:245-7.
8. Bordei P, Sapte E, Iliescu D. Double renal arteries originating from the aorta. *Surg Radiol Anat* 2004;26: 474-9.
9. Gwon DI, Ko GY, Yoon HK et al. Inferior phrenic artery: anatomy, variations, pathologic conditions and interventional management. *Radiographics* 2007;27: 687-705.
10. Baniel J, Foster RS, Donohue JP. Surgical anatomy of the lumbar vessels: implications for retroperitoneal surgery. *J Urol* 1995;153:1422-5.
11. Silveira LA, Silveira FB, Fazan VP. Arterial diameter of the celiac trunk and its branches. *Anatomical study*. *Acta Cir Bras* 2009;24: 43-7.
12. Best IM, Pitzele A, Green A, Halperin J, Mason R, Giron F. Mesenteric blood flow in patients with diabetic neuropathy. *J Vasc Surg* 1991;13: 84-90.
13. Iimura A, Oguchi T, Shibata M, Takahashi T. An anomalous case of the hepatic artery arising from the superior mesenteric artery. *Okajimas Folia Anat Jpn* 2007;84:61-5.
14. Saldarriaga B, Perez AF, Ballesteros LE. A direct anatomical study of additional renal arteries in a Colombian mestizo population. *Folia Morphol (Warsz)* 2008;67:129-34.
15. Loukas M, Hullett J, Wagner T. Clinical anatomy of the inferior phrenic artery. *Clin Anat* 2005;18:357-65.
16. Basar R, Onderogul S, Cumhuri T, Yuksel M, Olcer T. Agenesis of the celiac trunk: an angiographic case. *Kaibogaku Zasshi* 1995;70:180-2.
17. Demirtas K, Gulekon N, Kurkcuoglu A, Yildirim A, Gozil R. Rare variation of the celiac trunk and related review. *Saudi Med J* 2005;26:1809-11.
18. Khamanarong K, Prachaney P, Utraravichien A, Tong-Un T, Sripaoraya K. Anatomy of renal arterial supply. *Clin Anat* 2004;17:334-6.