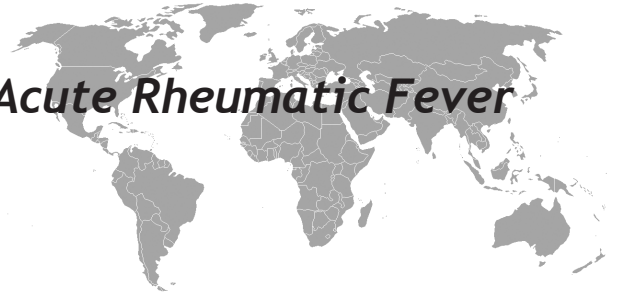

An Unusual Presentation of Acute Rheumatic Fever

Derya Arslan, Osman Guvenc, Derya Cimen, Bulent Oran



ABSTRACT

Acute rheumatic fever (ARF) is a multisystem disease caused by an immunological response to group A streptococcus infection. Its sequel rheumatic heart disease continue to cause a large burden of morbidity and mortality in developing countries. Early detection of ARF is paramount to the prevention of rheumatic heart disease. We report a case of ARF with presenting epistaxis. The variety of clinical manifestations, which may be the presenting signs and symptoms of ARF, are not included in the updated-revised Jones criteria. Therefore, a careful examination and awareness of the disease can play an important role in identifying ARF.

Key words: Rheumatic carditis, prevention, child, epistaxis

Akut Romatizmal Ateş'in Nadir Bir Bulgusu

ÖZET

Akut romatizmal ateş (ARA) grup A streptokok enfeksiyonuna grubuna bir immünolojik cevabın neden olduğu multisistem bir hastalıktır. Gelişmekte olan ülkelerde romatizmal kalp hastalığı sekeli morbidite ve mortalitenin büyük bir yük nedeni olmaya devam etmektedir. ARA'nın erken tanısı romatizmal kalp hastalığının önlenmesinde çok önemlidir. Biz burun kanaması ile başvuran iki ARA olgusunu sunduk. ARA'nın belirti ve bulgularını içeren klinik belirtilerinin çeşitliliği revize Jones kriterlerinde yer almamaktadır. Bu nedenle dikkatli bir muayene ve hastalığın farkındalığı ARA'nın saptanmasında önemli bir rol oynayabilir. Biz sunan burun kanaması ile ARF olgusunu.

Anahtar kelimeler: Romatizmal kardit, önlem, çocuk, burun kanaması

INTRODUCTION

Acute rheumatic fever is a public health concern due to carditis and heart damage, which may be aggravated by late diagnosis and poor penicilin prophylaxis adherence. It is a diffuse inflammatory process involving the connective tissues that appears in approximately 0.3 percent of untreated patients suffering infections of the upper respiratory tract by the group A beta haemolytic streptococcus. Within the developing countries, it remains a common cause of acquired heart disease. There is no only, gold standard, pathognemonic investigation for ARF. The valid diagnostic criteria for ARF are clinically and laboratory based. Therefore, the diagnosis of ARF is clinically based using the revised Jones criteria (1,3,6). Additionally, the evidence of preceding group A streptococcal pharyngitis was added to the list of minor

manifestations in the modified Jones criteria and the evidence of a prior streptococcal infection was considered essential for the diagnosis of RF in the 1965 revision of the Jones criteria. It was suggested that exclusion of clinical syndromes of non-streptococcal origin would further increase the accuracy of the criteria (6).

CASE

The patient, a 15-year-old boy, had developed fever, a sore throat and silent abdominal pain three week previously. Him infection of the upper respiratory tract had been treated for five days with ampicillin-sulbactam. He was admitted to our hospital with epistaxis existing since the first week. On examination, there was a persistent sinus tachycardia, at 124 beats per minute, but he was

Department of Pediatric Cardiology, Selcuk University Medical Faculty, Konya, Turkey

Received: 08.01.2014, Accepted: 03.12.2014

Correspondence: Derya Arslan,
Department of Pediatric Cardiology, Selcuk University Medical Faculty, Konya,
Turkey 42075 Konya-Turkey
Tel: 903322415000 Fax: 903323236723
E-mail: aminederya@hotmail.com

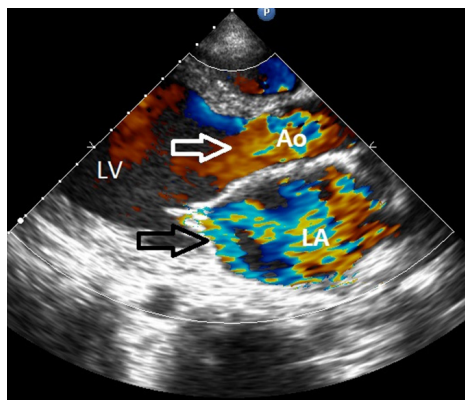


Figure 1. Transthoracic echocardiography view of patient with acute rheumatic fever showing severe mitral valve regurgitation (black arrow), second degree aortic valve regurgitation (white arrow). LA; left atrium, LV; left ventricle, Ao; aorta

normothermic, at 37.7 degrees centigrade. The blood pressure was 110/40 mmHg. The cardiac auscultation revealed a pansystolic murmur, of grade 3-4 out of 6 audible at the apex and radiating to the left axilla and an early diastolic murmur heard at the left and right side of the sternum. Other systemic examinations were normal. Laboratory tests revealed haemoglobin of 9.1 grams per decilitre; the white blood cell count at 13,600 per cubic millimetre, with 62 percent polymorphonuclear cells; a platelet count of 415,000 per cubic millimetre; titres of antistreptolysin O at 973 international units; levels of C reactive protein at 67 mg/l, and an erythrocytic sedimentation rate of 80 millimetres per hour. Other

biochemical analysis, including international normalised ratio (INR), else coagulation tests, antinuclear antibodies, rheumatoid factor, viral serology and thyroid function tests were normal. An electrocardiogram revealed sinus tachycardia.

The cross-sectional and Doppler echocardiography demonstrated that too heavy mitral insufficiency, second-third degree aortic insufficiency, highly enlarged left ventricle (Figure 1,2). The cultures of the throat, blood and urine were negative. Because of the clinical and laboratory findings satisfied the Jones criterions for the diagnosis of acute rheumatic carditis (1,3,4), we commenced treatment with prednisolone, and prophylactic benzathine penicillin. However, positive inotropic agents and diuretics were initiated. The patient recovered dramatically. Ten days later, acute phase reactants were normal. The systolic function of the heart began to improve. After a month, he was discharged from hospital in good condition, albeit still with aortic (first degree) and mitral insufficiency (first-second degree).

DISCUSSION

Our patient had carditis and elevated acute phase reactants on the background of a history of recent pharyngeal infection and a positive antistreptococcal antibody test.

A systematic and carefully evaluation of patients are very important to define for disease and treatment. A predictive diagnosis of ARF may be made, when a patient presents one minor criteria and several other manifestations such as anemia, abdominal pain, rheumatic pneumonia, unilateral pulmonary edema, atypical articular involvement, silent carditis, low-grade fever rapid sleeping pulse rate, tachycardia out of proportion to fever, malaise, epistaxis, precordial pain and an elevated level of IgG, IgA, C3 and circulating immune complexes (5-7). Our unusual presentation was the epistaxis on admission of the patient. Although the patient was not examined carefully, the diagnosis of rheumatic carditis was not performed probably. In approximate 50% of cases of ARF, cardiac involvement will be evident although severe decompensated cardiac failure is rare. Acute rheumatic fever can affect any layer of the heart (pericardium, myocardium, endocardium) in the acute phase. The carditis has been regarded as a pancarditis with cardiac failure. Rheumatic carditis is based on

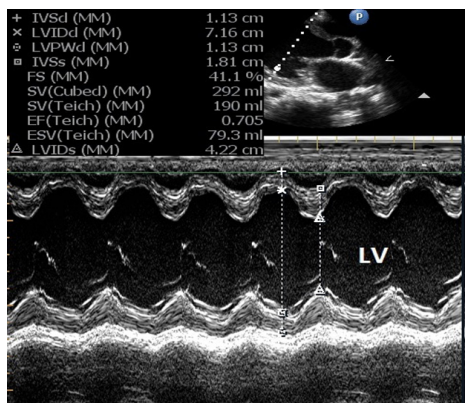


Figure 2. M-mode measurements shows left ventricular dilatation. LV; left ventricle.

the presence of significant apical systolic and/or basal diastolic murmurs, clinical presence of pericarditis and/or unexplained congestive heart failure. However, silent carditis was reported with an incidence which varied between 7% and 47%, depending on the phase which the disease has reached when the echocardiography is performed (6). The echocardiography examination will quickly confirm the presence or absence of valvular involvement when a clinically detectable murmur is present (1,4,6). Echocardiographic evaluations have reinforced the notion that valvular disease rather than myocardial disease is the primary cardiac abnormality responsible for the development of cardiac failure (2,8). The echocardiography in our patient showed mildly impaired left ventricular systolic function and serious left ventricular dilatation due to severe mitral aortic valve regurgitation.

The most suitable treatment of ARF remains unclear, anti-inflammatory agents including corticosteroids are frequently used. Also, long-acting benzathine penicillin is the recommended treatment, with the first dose prescribed at diagnosis, followed by continuous 3-week interval age-appropriated dosing, according to WHO experts guidelines (2,4).

Acute rheumatic fever is caused by a group A streptococcal pharyngeal infection. Children suffering from a throat infection a group A streptococcal pharyngeal infection should be treated correctly and fully. The diagnosis of ARF is clinically based using the revised American Heart Association endorsed 1992 Duckett Jones Criteria. The evidence of two major criteria or one major and two minor criteria is required with supporting evidence of streptococcal infection, for example, positive throat culture or rapid antigen test for group A streptococcal or raised or rising streptococcal antibody titre for a diagnosis of ARF. Also the criteria for diagnosis are well known, the clinical signs and symptoms needed to make the diagnosis do not always appear concurrently. The first complaint may be mild, short-lived and therefore the diagnosis may be missed or delayed. It is important to make an early diagnosis of ARF so that valvular damage can be minimised during the initial attack and further episodes and long-term sequelae can be prevented. Secondary prophylaxis to avoid recurrences is the most effective approach to control ARF and rheumatic heart disease.

REFERENCES

1. Carapetis JR, McDonald M, Wilson NJ. Acute rheumatic fever. *Lancet* 2005;366:155-68.
2. Ferrieri P. Proceedings of the Jones Criteria workshop. *Circulation* 2002;106:2521-3.
3. Gerber MA, Baltimore RS, Eaton CB, et al. Prevention of rheumatic fever and diagnosis and treatment of acute Streptococcal pharyngitis: a scientific statement from the American Heart Association Rheumatic Fever, Endocarditis, and Kawasaki Disease Committee of the Council on Cardiovascular Disease in the Young, the Interdisciplinary Council on Functional Genomics and Translational Biology, and the Interdisciplinary Council on Quality of Care and Outcomes Research: endorsed by the American Academy of Pediatrics. *Circulation* 2009;119:1541-51.
4. El-Menyar A, Al-Hroob A, Numan MT, Gendi SM, Fawzy IM. Unilateral pulmonary edema: unusual presentation of acute rheumatic fever. *Pediatr Cardiol* 2005;26:700-2.
5. Kula S, Olguntürk R, Ozdemir O. Two unusual presentations of acute rheumatic fever. *Cardiol Young* 2005;15:514-6.
6. Carvalho SM, Dalben I, Corrente JE, Magalhaes CS. Rheumatic fever presentation and outcome: a case-series report. *Rev Bras Reumatol* 2012;52:241-6.
7. Smith MT, Lester-Smith D, Zurynski Y, Noonan S, Carapetis JR, Elliott EJ. Persistence of acute rheumatic fever in a tertiary children's hospital. *J Paediatr Child Health* 2011;47:198-203.
8. Khriesat I, Najada AH. Acute rheumatic fever without early carditis: an atypical clinical presentation. *Eur J Pediatr* 2003;162:868-71.