

BRONCHIAL CARCINOMA PRESENTING WITH PNEUMOTHORAX

Okan Solak¹, Adnan Sayar², Muzafer Metin², Akif Turna², Atilla Pekçolaklar², Atilla Gürses²

Kocatepe University School of Medicine. Department of Thoracic Surgery, Afyon¹, Yedikule Hospital for Chest Diseases and Thoracic Surgery, Department of Thoracic Surgery, İstanbul², Turkey

Spontaneous pneumothoraxs are usually caused by subpleural apical blebs but may also be secondary to metastasis to the lung and rarely primary lung cancer. We present a 56-years-old man with spontaneous pneumothorax secondary to non-small cell lung cancer.

Key words: Lung cancer, spontaneous pneumothorax

Eur J Gen Med 2006; 3(2):78-79

INTRODUCTION

Spontaneous pneumothorax in young adults is relatively common. The overall incident is estimated at 5 to 10 per 100,000 per year and as high as 1 in 500 young men (1). Pneumothorax is usually the result of the rupture of an apical lung bleb but may also be secondary to underlying pulmonary pathology such as emphysema, tuberculosis, eosinophilic granuloma and rarely lung neoplasm (2). We report the case of the non-small cell lung cancer presenting as spontaneous pneumothorax.

CASE

A 56 years old man administered to a community hospital with sudden shortness of breath and chest pain. He had a left spontaneous pneumothorax at chest radiograph. A chest tube was inserted (Figure 1), but an air leak persisted for 4 days. He was referred to our institution. He had complained from left shoulder pain and dyspnea 2 days before he administered to the hospital. When he administered to hospital he had severe dyspnea. He was a retired laborer. He had smoked 1 pocket cigarettes in a day for 20 years. On arrival, he wasn't in distress and his physical examination was essentially normal. A chest computed tomography (CT) scan revealed left pneumothorax and a centrally located cavitary 3x4 cm lesion (Figure 2). CT scan also showed a closed relationship

between the lesion and pulmonary artery and also superior pulmonary vein. A fiberoptic bronchoscopy disclosed a vegetative mass obstructing left upper lobe bronchus. Pathology of the needle biopsy taken from the mass indicated squamous carcinoma. He had a diagnosis of primary pulmoner cancer. A mediastinoscopy was accomplished. No mediastinal lymph node metastasis was found. An exploratory thoracotomy was done via posterolateral thoracotomy. However, an intrapericardial involvement of the tumor through superior pulmonary vein was noticed and the tumor was deemed to be irresectable. The surgical stage of the tumor was found to be T4N0M0. He was referred to an oncology department.

DISCUSSION

Pneumothorax is an unusual presentation of lung metastasis and was described by Barrin in 1937 (1). Tumors associated with pneumothorax include sarcoma; Ewing's sarcoma; teratoma; Wilm's tumor; malignant melanoma; carcinoma of the cervix, pancreas, or kidney; leiomyosarcoma of the uterus; and most commonly, osteogenic sarcoma (2). The incidence of concurrent spontaneous pneumothorax and lung cancer was reported as 0.003-0.005 (3,4). Majority of the cases were male and the mean age was 57. Usually, pneumothorax initially veiled concurrent pulmonary mass. The most common histology

Correspondence: Okan Solak, MD

Adress: Örnekevler M. Kocatepe C. Dönerkaya Apt. No: 2/3 Merkez. Afyon-TURKEY

Tel: 902722171392, Fax: 902722172029

E-mail: okanchest@yahoo.com

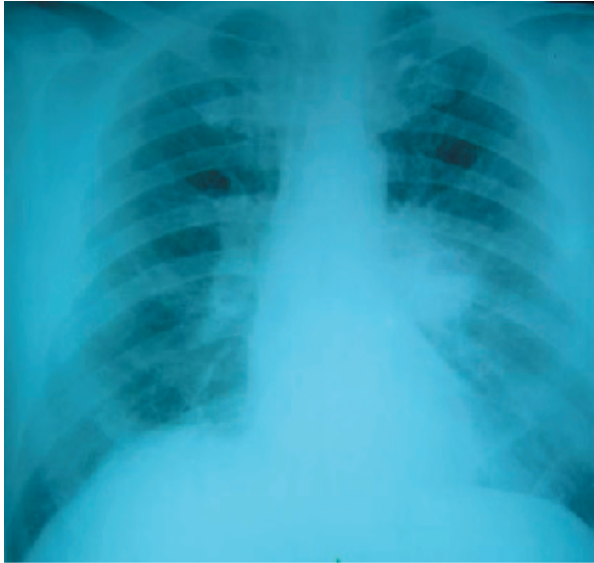

Figure 1. Posteroanterior chest radiography showing central lesion

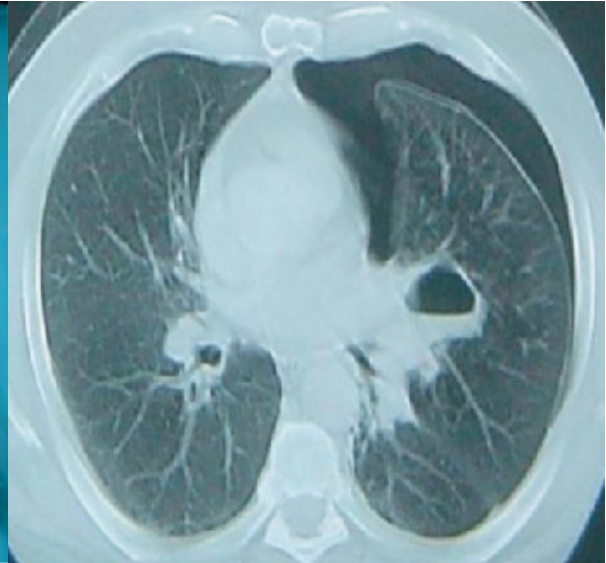


Figure 2. CT scan of patient

was squamous cell carcinoma (50%) (4).

Two mechanisms have been speculated for pneumothorax secondary to cancer (3). The first consists of tumor emboli in a subpleural position with infarction of the lung, necrosis, and air leakage. The second mechanism involves tumor growth causing obstruction as a ball – valve effect, resulting in the disruption of the alveoli and leaking of air, which dissects into subpleural space and forms blebs that rupture (3).

Our patient had a 3x4 cm cavitory lesion and there was no direct communication between pleural space and cavity of the lesion. There was a tumor protruding from the posterior wall of upper lobe bronchus. There had been no air leak. We considered that this place could be the probable cause of pneumothorax.

Spontaneous pneumothorax is relatively frequent in young patients and is usually primary in nature and due to rupture of an apical subpleural blep. However, one should keep in mind the possibility of pneumothorax occurring secondary to a primary lung cancer.

REFERENCES

1. De Barrin J. Haemopneumothorax spontane dans une metastase pulmonaire de sarcoma osseux. *Bull Mem Soc Radiol Fr* 1937;25:73
2. Ouellette D, Inclet R. Unsuspected metastatic choriocarcinoma presenting as unilateral spontaneous pneumothorax. *Ann Thorac Surg* 1992;53:144-5
3. Kuzucu A, Soysal O, Yakinci C, Aydin EA. Pleuropulmonary blastoma: report of a case presenting with spontaneous pneumothorax. *Eur J Cardiothorac Surg.* 2001 Feb;19(2):229-30
4. Steinhauslein A, Cuttat FJ. Spontaneous pneumothorax, a complication of lung cancer. *Chest* 1985;88:5