

# Carbon Monoxide Poisoning Presenting with Atrial Fibrillation

Ahmet Avci, Ahmet Yılmaz, Kenan Demir, Mustafa Celik, Recep Karatas

## ABSTRACT

Carbon monoxide intoxication is one of the most common types of poisoning and it is the leading cause of death by poisoning in the world. We report a carbon monoxide intoxication case presenting with atrial fibrillation on 17 years old healthy boy. 17 years old boy admitted to emergency service after exposing carbon monoxide gas approximately 3 hours. His first electrocardiography (ECG) showed atrial fibrillation with rapidly ventricular response. After oxygen supply sinus rhythm was achieved spontaneously. Emergency physicians should be aware of the clinical presentation of carbon monoxide intoxication. Every patient that arrived emergency service with acute or chronically carbon monoxide poisoning should undergo cardiovascular investigation, including ECG and measurement of cardiac enzymes.

**Key words:** Carbon monoxide, intoxication, atrial fibrillation

## Karbonmonoksit Zehirlenmesine Bağlı Gelişen Atriyal Fibrilasyon

### ÖZET

Karbonmonoksit (CO) zehirlenmesi zehirlenme türleri arasında en sık görülenlerindedir. Bu çalışmada CO gazına bağlı akut zehirlenme geçiren, 17 yaşında, atriyal fibrilasyon için ek risk faktörü olmayan erkek hastada gelişen paroksizmal atriyal fibrilasyon vakasını takdim ettik. Geri dönüşsüz maske ile oksijen tedavisi verildikten sonra seri kangazı takiplerinde hastanın karboksihemoglobin seviyelerinin düştüğünü ve hastanın ritminin atriyal fibrilasyondan, spontan sinüs ritmine döndüğünü gördük. Bu nedenle CO zehirlenmesi sonucu gelişen atriyal fibrilasyon tedavisinde hastanın hemodinamik parametreleri stabil ise maske ile oksijen solutulmasının ilk tedavi seçeneği olması gerektiğini düşündük. Bu vakada; hastanın 17 yaşında olması, atriyal fibrilasyon açısından hiçbir risk faktörünün olmaması ve karboksihemoglobin seviyesindeki düşüşe paralel olarak hastanın spontan sinüs ritmine dönmüş olması; CO zehirlenmesi ve atriyal fibrilasyon gelişimi arasındaki ilişki açısından anlamlı idi.

**Anahtar kelimeler:** Karbonmonoksit, intoksikasyon, atriyal fibrilasyon

## INTRODUCTION

Carbon monoxide intoxication is one of the most common types of poisoning and it is the leading cause of death by poisoning in the world (1). Carbon monoxide is known as a silent killer; because it is an odorless, colorless, non-irritating gas. The clinical findings of carbon monoxide poisoning are highly variable (2). Mild exposures result in headache, nausea, dizziness, myalgia, mental confu-

sion and severe exposures to carbon monoxide result in convulsion, coma and death. Neurological and cardiovascular symptoms are very common (1). Acute coronary syndrome, myocardial dysfunction, ischemia, infarct, cardiac fibrosis, atrial thrombus and cardiac arrest are cardiac pathologies reported in carbon monoxide intoxication. Sinusal tachycardia is the most common cardiac finding (3-4). Also atrial fibrillation, atrial premature

Selçuk University Faculty of Medicine, Department of Cardiology, Konya/Turkey

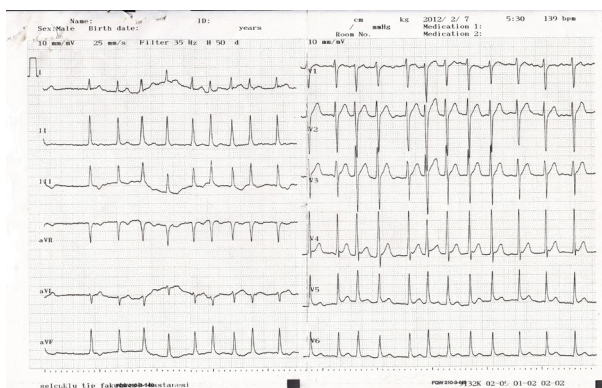
Received: 26.04.2014, Accepted: 09.10.2014

Correspondence: Ahmet Yılmaz  
Selçuk Üniversitesi Tıp Fakültesi Kardiyoloji AD, 42075 Kampüs/Konya/Türkiye  
Telephone number: +90 532 632 9115 Number: +90 332 241 2151  
E-mail: dr.ahmetyilmaz@gmail.com

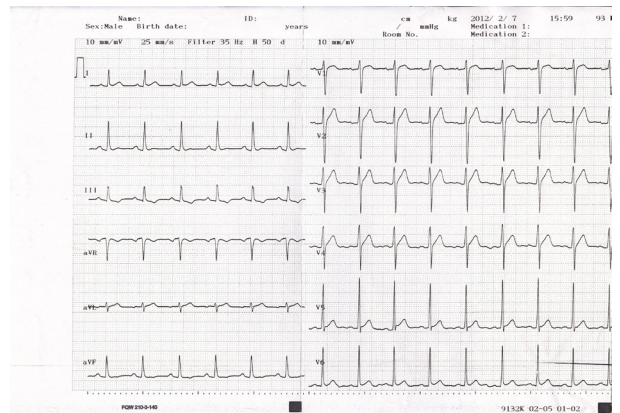
systoles, wandering pacemaker, ventricular extrasystoles, ventricular tachycardia and fibrillation have been reported (5-7). These arrhythmias may occur because of myocardial toxicity or a direct effect of carbon monoxide on myocardial mitochondria. The most common cause of mortality on acute carbon monoxide poisoning are these arrhythmias (8). Here we reported a rare case of acute carbon monoxide poisoning in a 17 years old healthy boy complicated with paroxysmal atrial fibrillation without any risk factor for atrial fibrillation.

## CASE

A 17 year old boy was found at unconscious condition by his father with his daughter and mother at the same room, after exposing to carbon monoxide approximately 3 hours. The patient was admitted to emergency service by ambulance. Only oxygen supply with non rebreathnig mask was given during transportation. On arrival the patient has spontaneous breathing but the unconscious condition is still continuing. Vital signs showed a disrhythmic heart rate 136 beats/min, a respiratory rate of 22 breaths/min and his blood pressure was 110/70mmHg. The first ECG showed atrial fibrillation (Figure 1). The first blood gas analyse revealed Ph of 7.38, PCO<sub>2</sub> of 45mmHg, PO<sub>2</sub> of 245 mmHg, SO<sub>2</sub> of 92.9 % and carboxyhemoglobin (COHb) of 23.9%. He had normal blood count, hepatic, serum electrolytes (Potassium level: 4,2mg/dl), renal and thyroid function tests. The patient was consulted to our cardiology clinic because of high ventricular response atrial fibrillation.



**Figure 1.** Twelve lead ECG at the time of admission to the emergency service showing high ventricular response atrial fibrillation. HR: 136 Bpm



**Figure 2.** Twelve lead ECG after 9 hours of admission to the emergency service showing sinus rhythm. HR: 93 Bpm

The patient was examined at emergency service. Oxygen supply with non breathing mask, intra venous fluid supply and anti-emetic medication due to his symptoms were given. Echocardiographic examination performed subsequently, demonstrated normal ejection fraction and valvular functions, and systolic pulmonary arterial pressure was <25 mmHg. To explore the potential damage of myocardium, troponin I and creatinin kinase-MB levels was measured and serial measurement in 6 hour periods was planned. The second blood arterial gas analyse was revealed Ph of 7.39, PCO<sub>2</sub> of 38.8mmHg, PO<sub>2</sub> of 79.4 mmHg, SO<sub>2</sub> of 97.1 % and COHb of 9.2%. After oxygen treatment the COHb levels was decreasing, his hemodynamical parameters was normal and also the patient has not any risk factor for atrial fibrillation, so we did not performed medical or electrical cardioversion. After 9 hours of admission to the emergency service, the sinus rhythm was achieved spontaneously (Figure 2). The last blood arterial gas analyse after achieving sinus rhythm was revealed Ph of 7.38, PCO<sub>2</sub> of 39.6mmHg, PO<sub>2</sub> of 149 mmHg, SO<sub>2</sub> of 98.1 % and COHb of 0.0 %. The cardiac enzymes were normal. The patient externated in healty condition after two days from emergency service. He was asymptomatic at first month cardiology visit.

## DISCUSSION

Carbon monoxide is one of the leading causes of poisoning-related deaths in Turkey. It binds to haemoglobin with greater affinity than oxygen and forms COHb which

leads to impaired oxygen transportation and subsequent tissue hypoxia by shifting the oxyhemoglobin dissociation curve to the left. Carbon monoxide exposures also cause inflammation through multiple pathways that are independent to the pathways to hypoxia, resulting in neurological and cardiac injury (8). As a result carbon monoxide poisoning causes cardiac damage by hypoxia and inflammation pathways. So every patient that arrived emergency service with acute or chronically carbon monoxide poisoning should undergo cardiovascular investigation, including ECG and measurement of cardiac enzymes. Including adult and paediatric patients, most of time it is very difficult to identify patients with carbon monoxide - induced cardiac damage. If cardiac injury or ECG abnormalities are present, a cardiology consultation is indicated (7-10,12).

No correlation was found between COHb levels and myocardial injury. Several patterns of ECG alternations have been described following either acute or chronic carbon monoxide exposure; these changes may be quickly reversible, delayed or prolonged. And also no correlation was found between COHb levels and ECG alternations ( 6, 8, 11). The half-life of carbon monoxide while a patient is breathing room air is nearly 300 minutes but decreases to approximately 90 minutes while breathing high-flow oxygen via a non-rebreathing mask and 30 minutes during hyperbaric oxygen treatment (12). In this case; the patient is 17 years old, he has not any risk factor for atrial fibrillation and correlated to the decrease in the level of COHb the rhythm was returned spontaneously to the sinus rhythm; so the relationship between development of atrial fibrillation and carbon monoxide poisoning was significant.

Teksam et al. (4) researched 131 patients between the ages of 6 months-17years with carbon monoxide poisoning, found that 30.5% of them has sinus tachycardia. However, atrial fibrillation was not observed in any patients in their study (4).

There was no atrial fibrillation case reported before, in age group smaller than 18 years old and there was no risk factor for atrial fibrillation in this patient. Spontaneous sinus rhythm was achieved without medical or electrical cardioversion according to decreasing COHb levels in blood gas analyze. So all of these situations make this case report significant.

## REFERENCES

1. Hampson NB. Trend in incidence of carbon monoxide poisoning in the United States. *Am J Emerg Med* 2005;23:838-41.
2. Weaver LK. Clinical practice. Carbon monoxide poisoning. *N Engl J Med* 2009;360:1217-25.
3. Colomp-Lippa D. Acute carbon monoxide exposure: Diagnosis, evaluation, treatment. *JAAPA* 2005;18:41-6.
4. Teksam O, Gumus P, Bayrakci B, Erdogan I, Kale G. Acute cardiac effects of carbon monoxide poisoning in children. *Eur J Emerg Med* 2010;17:192-6.
5. Thiels H, Van Durme JP, Vermeire P, Pannier R. Immediate and late electrocardiographic changes in the course of acute carbon monoxide poisoning. *Lille Medical* 1972;17:191-5.
6. Carnevali R, Omboni E, Rossati M, Villa A, Checchini M. Electrocardiographic changes in acute carbon monoxide poisoning. *Minerva Med* 1987;78:175-8.
7. Lindell K. Carbon monoxide poisoning. *N Engl J Med* 2009;360:1217-25.
8. Satran D, Henry CR, Adkinson C, Nicholson CI, Bracha Y, Henry TD. Cardiovascular manifestations of moderate to severe carbon monoxide poisoning. *J Am Coll Cardiol* 2005;45:1513-6.
9. Yanir Y, Shupak A, Abramovich A, Reisner SA, Lorber A. Cardiogenic shock complicating acute carbon monoxide poisoning despite neurologic and metabolic recovery. *Ann Emerg Med* 2002;40:420-4.
10. Gandini C, Castoldi AF, Candura SM, et al. Cardiac damage in pediatric carbon monoxide poisoning. *J Toxicol Clin Toxicol* 2001;39:45-51.
11. Gandini C, Castoldi AF, Candura SM, et al. Carbon monoxide cardiotoxicity. *J Toxicol Clin Toxicol* 2001;39:35-44.
12. Hsu PC, Lin TH, Su HM, et al. Acute carbon monoxide poisoning resulting in ST elevation myocardial infarction: a rare case report. *Kaohsiung J Med Sci.* 2010;26:271-5.