





First trimester recurrent pregnancy loss due to balanced chromosomal translocations in husband: A case report

Tuan Nadrah Naim Tuan Ismail ^{1,2} , Noraini Mohamad ^{1,2*} , Zainab Mat Yudin ^{1,2} , Nazihah Mohd Yunus ^{2,3} 

¹School of Dental Sciences, Universiti Sains Malaysia, Kelantan, MALAYSIA

²Hospital Universiti Sains Malaysia, Health Campus, Kelantan, MALAYSIA

³Human Genome Center, School of Medical Sciences, Universiti Sains Malaysia, Kelantan, MALAYSIA

*Corresponding Author: mnoraini@usm.my

Citation: Naim Tuan Ismail TN, Mohamad N, Mat Yudin Z, Mohd Yunus N. First trimester recurrent pregnancy loss due to balanced chromosomal translocations in husband: A case report. *Electron J Gen Med.* 2023;20(1):em440. <https://doi.org/10.29333/ejgm/12702>

ARTICLE INFO

Received: 29 Oct. 2022

Accepted: 27 Nov. 2022

ABSTRACT

Early pregnancy loss in a wanted pregnancy is stressful and frustrating to any couple. It becomes even more emotionally traumatic when it occurs repeatedly. Two or more of early pregnancy loss is known as recurrent pregnancy loss (RPL). RPL is a clinical challenge for physicians to unriddle. In this case report, we illustrate a case of a 40-year-old woman who experienced six recurrent first-trimester pregnancy losses. After the third pregnancy loss, initial maternal blood investigations were done, and the results were normal. After the fifth miscarriage, both partners' blood was tested for the cytogenetic study, and her cytogenetic analysis revealed a normal karyotype. However, the paternal showed balanced translocation 46, XY, t(6;13) (q13;14.1) with a balanced translocation between the long arm of chromosome 6 at position 6q13 and the long arm of chromosome 13 at position 13q14.1. When the initial blood investigation is considered normal, a chromosomal study is one of important etiological investigation in couples with RPL.

Keywords: recurrent pregnancy loss, balanced translocation, karyotyping, cytogenetic study, chromosomal study

INTRODUCTION

A pregnancy that spontaneously ends before the fetus reaches viability is known as a miscarriage. The term refers to all pregnancies that end before 24 weeks of gestation [1]. There is various definition for recurrent pregnancy loss (RPL). The occurrence of three or more consecutive losses of clinically recognized pregnancies is known as recurrent pregnancy loss [2]. The European Society of Human Reproduction and Embryology released a 2017 consensus statement concluded that a diagnosis of RPL should be considered after the loss of two or more pregnancies [1].

There are primary and secondary types of RPL. Women who have never carried to viability (24 weeks gestation or beyond) are categorized as primary RPL. While a woman who has had a previous live birth is categorized as secondary RPL. The prognosis for a successful pregnancy is better with secondary RPL [1]. The exact prevalence of RPL is difficult to estimate, but study have reported that RPL affects 1-3% of couples attempting to bear children and 70% of sporadic miscarriages are caused by fetal chromosomal abnormalities [3]. The increase in maternal age, number of previous miscarriages, antiphospholipid syndrome, genetic factors (chromosomal abnormalities), anatomical factors, uterine anomalies, thrombophilia, hormonal or metabolic disorders, infection, autoimmunity, sperm quality, and lifestyle issues are

responsible for recurrent first and second-trimester miscarriage [2, 4].

HISTORY

A 40-year-old Malay woman, para 3+6, presented with six consecutive first-trimester complete miscarriages ranging from six to eight weeks period of amenorrhea (POA). The genetic status of the product of conception was unknown. She delivered two normal children with the same spouse, a daughter, and a son, in 2009 and 2010, respectively. The husband is 41 years old, and the marriage was non-consanguineous. Both partners were physically and intellectually normal. **Table 1** shows her past delivery history.

Table 1. Summary of the patient's past delivery history

Year	Delivery history
2009	Girl, term, spontaneous vagina delivery.
2010	Boy, term, spontaneous vagina delivery.
March 2015	Complete miscarriage at eight weeks POA.
June 2015	Complete miscarriage at seven weeks POA.
January 2016	Complete miscarriage at six weeks POA.
October 2017	Complete miscarriage at six weeks POA.
December 2017	Complete miscarriage at eight weeks POA.
October 2018	Complete miscarriage at six weeks POA.
March 2022	Boy, term, spontaneous vagina delivery.

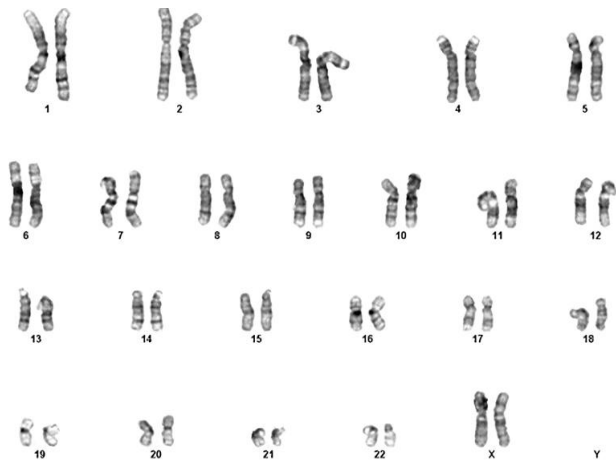


Figure 1. GTG banded metaphase of the mother showing normal 46, XX female karyotype pattern (reprinted with permission of the patient)

After the third miscarriage, RPL investigations were done. Her results were fasting blood sugar level at 4.8 mmol, two hours postprandial 6.4 mmol, thyroid stimulating hormone (TSH) 1.35 mIU/L, and thyroxine 4 (T4) 1.35 pmol/L.

Other investigations were negative, including antinuclear antibodies, rheumatoid factor, anti dsDNA, and anticardiolipin antibodies. Her full blood count, renal function and liver function test results were within the normal range. The transabdominal ultrasound scan showed normal uterus and ovarian structures.

After the 5th miscarriage, both partners' blood was tested for the conventional cytogenetic study. The wife's result revealed normal female karyotype 46, XX (**Figure 1**) but the cytogenetic analysis of the husband showed 46, XY, t(6;13) (q13;14.1) with a balanced translocation between the long arm of chromosome 6 at position 6q13 and the long arm of chromosome 13 at position 13q14.1 (**Figure 2**). There was no family history of genetic disorder on her side, but her husband has a nephew with unexplained autism and recurrent miscarriage. Unfortunately, she had another miscarriage after the cytogenetic analysis.

Three years later (July 2021), she got pregnant again, and during this time, the pregnancy endured till the second trimester. She requested a genetic study of the fetus as the couple fears the fetus would be abnormal. Amniocentesis was

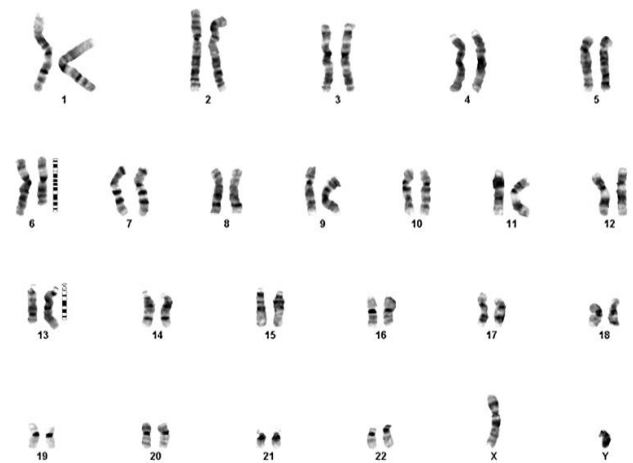


Figure 2. GTG banded metaphase of the father showing 46, XY, t(6;13) (q13;14.1) karyotype pattern. The arrow indicates the balanced translocation between the long arm of chromosome 6 at position 6q13 and the long arm of chromosome 13 at position 13q14.1 (reprinted with permission of the patient)

done at 17 weeks POA. The chromosome analysis of the fetus revealed a normal male karyotype (**Figure 3**). She delivered a normal full-term baby boy via spontaneous vagina delivery with a birth weight of 2.68 kg in March 2022.

DISCUSSION

RPL is a concern for couples planning future pregnancies [5]. A large retrospective study involving 1,020 women with two or more RPL found that 90% of the losses occurred in the first trimester (<13 weeks), with 44% of the patients experienced two consecutive losses, 34% had three, and 22% had four or more consecutive losses [6].

Numerous studies reported chromosomal abnormalities observed in approximately 3-4% of cases presented with RPL. In these studies, a partner was found to carry a balanced structural chromosomal anomaly, which is typically a balanced reciprocal or a Robertsonian translocation [5, 7, 8]. Chromosomal abnormalities, specifically in regards to balanced rearrangements, are common in couples with recurrent miscarriages [5]. A study in India that was conducted among 152 individuals (76 couples) who have experienced two

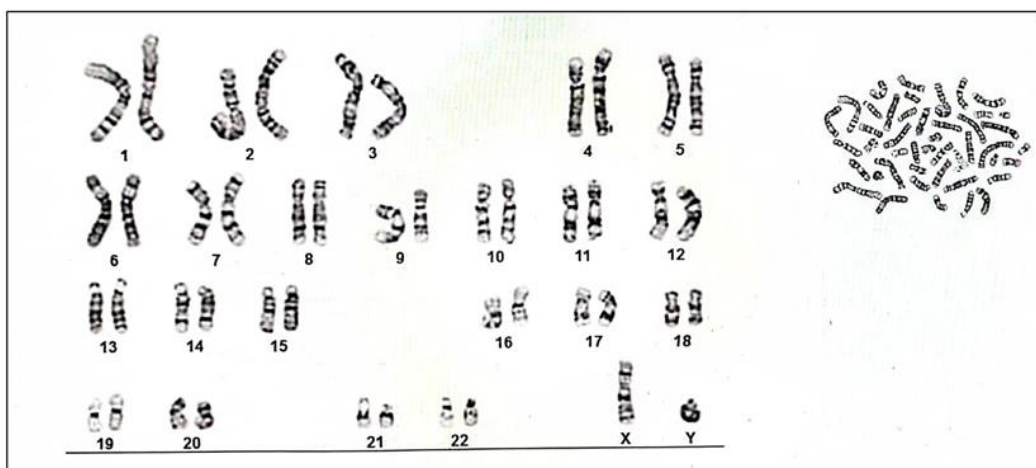


Figure 3. GTG banded metaphase of the fetus showing 46, XY normal male karyotype (reprinted with permission of the patient)

or more consecutive pregnancy losses during the second trimester (before 20 weeks of gestation) found balanced chromosomal translocations were detected in four out of five (80%) individuals with chromosomal abnormalities [7].

Chromosomal abnormalities were found to be prevalent. One study found balanced chromosomal translocations were observed in 72 out of 170 (42.35%) individuals with chromosomal abnormalities [5]. Another study found that balanced reciprocal translocations formed 60% of anomalies [8].

The size and genetic makeup of the rearranged chromosomal segments affect the likelihood of miscarriage. Miscarriage is still a possibility, even in phenotypically normal balanced translocation carriers. If the pregnancy is carried to term, the live birth may have multiple congenital malformations and/or mental disabilities [2]. Therefore, finding out whether a parent has such a rearrangement is helpful since it provides

- (1) an explanation for likelihood of future miscarriages,
- (2) informed risk for a live birth with serious anomalies,
- (3) prenatal diagnosis in a future pregnancy, and
- (4) information for extended relatives who might be at risk and might want to have chromosomal testing [7].

Most guidelines suggest evaluating and treating RPL after two consecutive miscarriages [1, 9]. The minimum diagnostic work-up for couples with RPL consists of a complete medical, surgical, genetic, and family history and a physical examination [9]. History of congenital abnormalities, mental retardation, infertility, spontaneous abortion, or perinatal mortality are relevant history for cases presented with chromosomal anomaly [7].

The initial evaluation of women with RPL includes a pelvic ultrasound to assess for uterine abnormalities, anticardiolipin antibody titer (IgG and IgM) and lupus anticoagulant for antiphospholipid syndrome, a thyroid function test for subclinical hypothyroidism, and a modified oral glucose tolerance test to screen for diabetes mellitus [2, 4]. If the results are normal, the following investigative step is parental and abortus karyotype. Given the low likelihood of an abnormal karyotype in couples with RPL, if the initial investigations show negative results this is the last test to be performed [9].

In this case, the initial investigations for RPL were only done after the third miscarriage, and all the investigations show normal results. The blood for the cytogenetic study of both husband and wife was sent only after the 5th miscarriage. Clinicians should be highly suspicious of the fetus's genetic abnormalities in RPL cases during the first trimester, if all other initial blood investigations in mothers show a normal result. The couples should have peripheral karyotyping performed to screen for any balanced structural chromosomal abnormalities. This is because, couples with balanced reciprocal translocation have a 50% chance of developing RPL and a 20% chance of giving birth to children with unbalanced chromosomal rearrangements [10]. The breakpoints and the implicated chromosomes determine whether balanced, unbalanced, or normal gametes are produced. The more significant the imbalance is the more likely a miscarriage will happen, whereas a subtle imbalance may increase the risk of having offspring with unbalanced karyotype [7].

The likelihood of a subsequent healthy live birth depends on the chromosome(s) involved and the type of

rearrangement. When one of the partners has a structural genetic abnormality, prenatal diagnosis through amniocentesis or chorionic villus sampling are the options to detect the genetic abnormality in the offspring [7]. Genetic counselling is essential for couples with identified structural genetic factors as it offers the prognosis of risk in future pregnancies [7].

In this case, she had secondary RPL as she had two previous live births before a recurrent pregnancy loss occurred, and the prognosis for her to have a successful pregnancy is better than women with primary RPL [1]. Therefore, prenatal diagnosis is essential for this patient if she gets pregnant again, as it would give an idea about the genetic arrangement of the offspring. In this case, after six miscarriages, her latest pregnancy was successful. A prenatal diagnosis via amniocentesis was carried out at 17 weeks POA fortunately revealed that the fetus has a normal karyotype.

CONCLUSION

The primary care physician and gynecologist should be highly suspicious of chromosomal abnormalities in RPL cases in the first trimester when all initial investigations show a normal result. The affected chromosome(s) and the type of rearrangement determine the likelihood of a future healthy live birth can vary. The parents' blood must be sent early for cytogenetic analysis to find the cause of RPL that occurred in the first trimester. When one of the partners has a structural genetic abnormality, prenatal diagnosis using amniocentesis or chorionic villus sample can be performed to identify the genetic problem in the children. Genetic counselling is important for couples with identified structural genetic factors as it offers the prognosis and risk of future pregnancies. By doing this, the couple is better prepared for the delivery and a plan can be made early if abnormalities are detected.

Author contributions: All authors have sufficiently contributed to the study and agreed with the results and conclusions.

Funding: No funding source is reported for this study.

Ethical statement: Authors stated that ethical approval was not required for the case report. Informed consent was obtained from the patient. Authors further stated that they have not exposed any particulars of the patient that can be identified and ensured that the information was for educational purposes only.

Declaration of interest: No conflict of interest is declared by authors.

Data sharing statement: Data supporting the findings and conclusions are available upon request from the corresponding author.

REFERENCES

1. European Society of Human Reproduction and Embryology. Guideline on the management of recurrent pregnancy loss. ESHRE Early Pregnancy Guideline Development Group. 2017. Available at: <https://www.eshre.eu/Guidelines-and-Legal/Guidelines/Recurrent-pregnancy-loss> (Accessed 20 August 2022).
2. Royal College of Obstetricians. Green-top guideline. No. 17. The investigation and treatment of couples with recurrent first-trimester and second-trimester miscarriage. RCOG. 2011. Available at: <https://poliklinika-harni.hr/images/uploads/2789/rcog-ponavljani-spontani-pobacaj.pdf> (Accessed 20 August 2022).

3. Rull K, Nagirnaja L, Laan M. Genetics of recurrent miscarriage: Challenges, current knowledge, future directions. *Front Genet.* 2012;3(34):1-13. <https://doi.org/10.3389/fgene.2012.00034> PMID:22457663 PMCID:PMC3306920
4. Practice Committee of the American Society for Reproductive Medicine. Evaluation and treatment of recurrent pregnancy loss: A committee opinion. *Fertil Steril.* 2012;98(5):1103-11. <https://doi.org/10.1016/j.fertnstert.2012.06.048> PMID:22835448
5. Sheth FJ, Liehr T, Kumari P, Akinde R, Sheth HJ, Sheth JJ. Chromosomal abnormalities in couples with repeated fetal loss: An Indian retrospective study. *Indian J Hum Genet.* 2013;19(4):415-22. <https://doi.org/10.4103/0971-6866.124369> PMID:24497706 PMCID:PMC3897136
6. Jaslow CR, Carney JL, Kutteh WH. Diagnostic factors identified in 1020 women with two versus three or more recurrent pregnancy losses. *Fertil Steril.* 2010;93(4):1234-43. <https://doi.org/10.1016/j.fertnstert.2009.01.166> PMID:19338986
7. Priya PK, Mishra VV, Roy P, Patel H. A study on balanced chromosomal translocations in couples with recurrent pregnancy loss. *J Hum Reprod Sci.* 2018;11(4):337-42. https://doi.org/10.4103/jhrs.JHRS_132_17 PMID:30787517 PMCID:PMC6333030
8. Sudhir N, Kaur T, Beri A, Kaur A. Cytogenetic analysis in couples with recurrent miscarriages: A retrospective study from Punjab, North India. *J Genet.* 2016;95(4):887-94. <https://doi.org/10.1007/s12041-016-0713-3> PMID:27994187
9. Tulandi T, Al-Fozan HM. Recurrent pregnancy loss: Definition and etiology. 2022. Available at: <https://www.uptodate.com/contents/recurrent-pregnancy-loss-definition-and-etiology#H34> (Accessed 20 August 2022).
10. Ocak Z, Ozlu T, Ozyurt O. Association of recurrent pregnancy loss with chromosomal abnormalities and hereditary thrombophilias. *Afr Health Sci.* 2013;13(2):447-52. <https://doi.org/10.4314/ahs.v13i2.35>