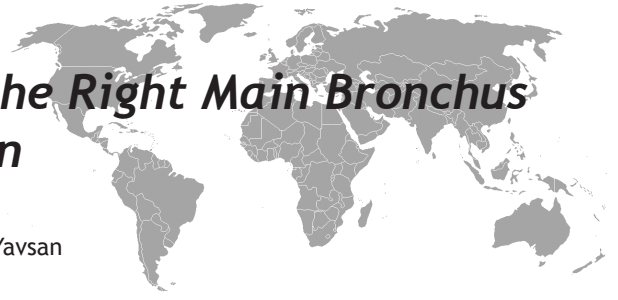

# Headscarf Pin Localized in the Right Main Bronchus and Two Pins in the Abdomen



<sup>1</sup>Burhan Apillioğulları, <sup>2</sup>Nuri Duzgun, <sup>2</sup>Hidir Esmе, <sup>3</sup>Mehmet Yavsan

## ABSTRACT

Tracheobronchial foreign body aspiration is a serious condition that might result in mortality and it necessitates emergency intervention. Studies in literature report cases of pin aspiration related to headscarf use in Muslim countries. The most frequent symptom in foreign body aspirations is coughing. Radio-opaque foreign bodies can be detected through lung radiology. Following diagnosis, the foreign body needs to be removed as soon as possible. The removal procedure is carried out by flexible fiberoptic bronchoscopy or rigid bronchoscope. We hereby present the case of a patient who presented to the emergency department with headscarf pin aspiration and whose radiography results revealed 2 pins in the abdomen and one pin in the right main bronchus.

**Key words:** Headscarf Pin, tracheobronchial foreign body, bronchoscopy

## Sağ Ana Bronşta Bir ve Karında İki Başörtüsü İğnesi Lokalizasyonu

### ÖZET

Trakeobronşiyal yabancı cisim aspirasyonu mortaliteye neden olabilen ve acil müdahale gerektiren ciddi bir durumdur. Literatürlerde Müslüman ülkelerde başörtüsü kullanımı ile ilgili iğne aspirasyon vakaları raporlanmıştır. Yabancı cisim aspirasyonunun en sık belirtisi öksürüktür. Radyo-opak ise yabancı cisim akciğer radyolojisi ile tespit edilebilir. Tanı konar konmaz, yabancı cisimin kısa sürede çıkarılması gerekir. Çıkarma işlemi fleksibl fiberoptik bronkoskop veya rijit bronkoskop tarafından yapılmaktadır. Burada, başörtüsü iğnesi aspirasyonu neticesinde acil servise başvuran ve radyografi sonuçlarında karında 2 ve sağ ana bronşta 1 adet tespit edilen bir olgu sunuyoruz.

**Anahtar kelimeler:** Başörtüsü iğnesi, trakeobronşiyal yabancı cisim, bronkoskopi

## INTRODUCTION

Foreign body aspiration refers to the inhalation of a foreign object into the upper or lower respiratory tract through the mouth or the nose (1). The most frequently aspirated objects include small scale appetizers (peanuts, hazel nuts, corn, sunflower seeds, etc.), organic fruit and vegetable particles, inorganic materials like pins (headscarf pins) and hair pins (2,3). Studies in literature reported case reports regarding pin aspirations during the fixing of headscarf pins in Muslim countries (3,4). Our case, however, is different in that the headscarf pins were located both in the lung and in the abdo

men. Women generally hold these pins with or without beading between their teeth while they put on their headscarves. A sudden cough, laugh, sneeze, or talk during this period may end up in the aspiration of the pin they were holding between their teeth. We aimed to present the treatment strategies regarding foreign body aspiration in our study with the case of our patient who had presented to the emergency department with the complaint of headscarf pin aspiration and whose radiological results had revealed 2 headscarf pins in her abdomen, and one pin in her right main bronchus.

<sup>1</sup>Necmettin Erbakan University Meram Medical Faculty, Thoracic Surgery, Konya,

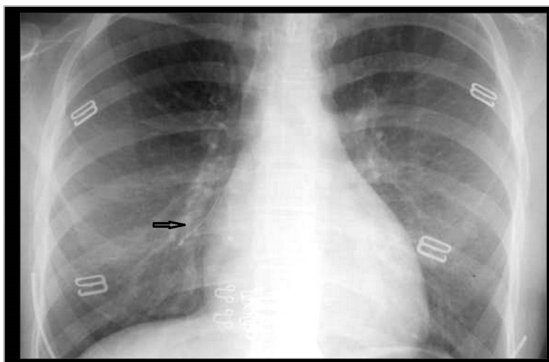
<sup>2</sup>Konya Training and Research Hospital, Thoracic Surgery, Konya, <sup>3</sup>Necmettin Erbakan University Meram Medical Faculty, Pulmonoloji, Konya

**Correspondence:** Burhan Apillioğulları,

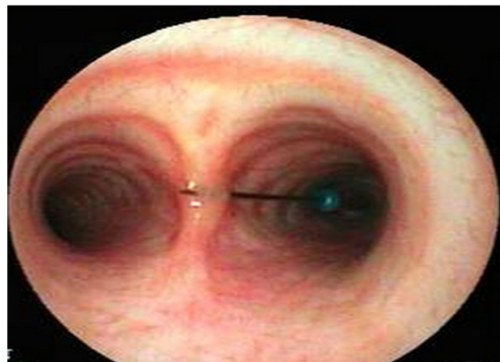Necmettin Erbakan University Meram Medical Faculty, Thoracic Surgery, Konya

e-mail: bapillioğullari@yahoo.com

Received: 24.10.2013, Accepted: 21.11.2013



**Figure 1.** A headscarf pin in the right main bronchus as revealed by the lung radiography obtained at the time of the patient's presentation to the emergency department



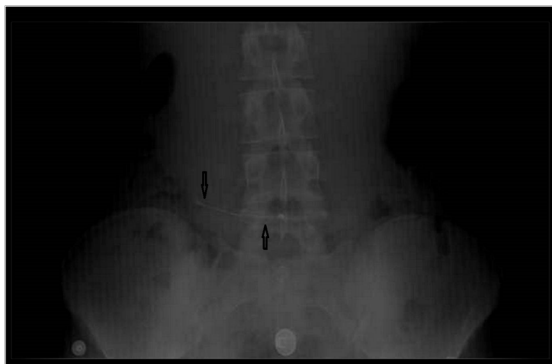
**Figure 3.** A headscarf pin in the right main bronchus

## CASE

A 16-year-old female patient presented to our emergency department complaining that headscarf pins got into her trachea. She stated that she had sneezed while she was holding 3 pins between her lips to straighten her headscarf and that all 3 pins got into her throat at that time. The patient had started coughing following aspiration and she had immediately presented to the emergency department. The patient's initial examination performed in the ER revealed that her general condition was good; she was conscious, oriented, and cooperative. Her blood pressure was 125/80mmHg, her pulse was 80 pulse/minute, her respiratory rate was 20 breath/minute, and oxygen saturation in room air was 95%. The patient's back-front lung radiography revealed 1 foreign body (headscarf pin) just near the right heart

shadow in the right hilar region and her direct abdominal graph at a standing position revealed 2 foreign bodies (headscarf pins) in the abdomen (Figure 1, 2).

Rigid bronchoscopy was performed on the patient. A headscarf pin was seen in the right main bronchus during rigid bronchoscopy and it was removed by a forceps. No complications occurred during the procedure. General surgery consultation was called for regarding the headscarf pins in the abdomen. The foreign bodies in the abdomen were followed up daily through direct abdominal graphs at a standing position by the suggestion of the general surgery department. The patient discharged both headscarf pins in the abdomen on the 2nd day of her hospitalization through defecation (Figure 3). The patient was discharged with full recovery on the 3rd day of her presentation to the emergency department.



**Figure 2.** Two headscarf pins in the abdomen as revealed by the direct abdominal radiography.

## DISCUSSION

Foreign body aspirations are closely related to age, sex, occupation, cultural life, socio-economic conditions, and traditions (3-5). It has been reported that more than 75% of foreign body aspirations happen to children between the ages of 0 to 3 (2-6). The fact that children of this age group frequently put objects into their mouths in order to get to know the objects and that their swallowing coordination has not fully developed are seen as the most significant reasons for aspiration. Headscarf aspiration does not only pose a risk to those using headscarf pins, but also to the children of the

family as an aspiratory object. In a study on headscarf pin aspiration by Dayioğlu et al., the authors reported 4 cases of children aged between 18 months and 2 years who had aspirated pins that they had found in their environment (7). Holding the pins between the lips while organizing the headscarves with both hands is a common practice among women wearing headscarves (8-9). These pins generally go into the tracheobronchial system while laughing, talking, or sneezing through a deep inspiration (8). Our case aspirated the pins that she had been holding between her lips when she sneezed.

The fact that headscarf pins are lighter than other metal pins and that their beaded (plastic) tips serve as parachutes enable them to go deeper in the lungs. It is known that the aspirated foreign bodies generally go into the right main bronchus because of its vertical position (10). The headscarf pin in our case was also located in the right main bronchus. It is mainly asymptomatic after the intake of the foreign body following excessive coughing (3). Our patient did not have any other complaints other than coughing at the time of aspiration either. Dyspnea, chest pain, hemoptysis, and fever can be rarely seen in foreign body aspirations. Direct lung radiography is of diagnostic significance because of the metallic structure of the pin and it also refers to the place and localization of the pin (11). Although computerized tomography is not routinely performed, it is known that CT scan is useful in showing the localization of the pin and the complications that might develop (12). We too used lung radiography and did not need tomography in the diagnosis of our patient. Further, we also detected 2 headscarf pins located in the stomach through direct abdominal radiography at a standing position.

Bronchoscopy should be performed in case of a foreign body aspiration even if the suspicion is not supported by anamnesis, radiological and clinical symptoms. The early diagnosis and treatment of tracheobronchial foreign bodies are significant. The removal of the pin can be performed by flexible fiberoptic bronchoscopy but rigid bronchoscopy performed under general anesthesia is the most effective and dependable approach in thracheobronchial foreign body aspirations. Thracotomy should be performed as soon as possible in cases where the foreign body could not be removed by bronchoscopic intervention. The removal of foreign bodies by bronchoscopy through all the technological developments in experienced hands pushed the morbidity and mortality rates under 1% (13). The general approach to

pins located in the abdomen is daily follow-up by direct abdominal radiography at a standing position. Our patient, too, discharged 2 pins through defecation on the 2nd day. The patient, who had no foreign bodies in her follow-ups through direct abdominal radiography at a standing position and back to front lung radiography, was discharged with full recovery on the 3rd day of her presentation to the ER.

As a result, headscarf pin aspiration is a frequently seen condition especially in women wearing headscarves. Therefore, it is necessary to inform individuals wearing headscarves and to take informative measures regarding pin aspiration. Another fact that should also be remembered is that headscarf pins held between the lips do not only go into the respiratory tracts but may also go into the gastrointestinal system through the esophagus as was the case with our patient. Thus, physicians will not miss a foreign body in the abdomen through direct abdominal radiography at a standing position in cases with suspicious anamneses.

#### REFERENCES

1. Beşerli K, Demirkaya A. Tracheobronchial foreign body aspiration. (Turkish) *Respiratory* 2003; 5; 316-9.
2. Yuncu G, Alıcı H, Sevinç S, Ünsal Ş. Tracheobronchial foreign body aspiration. *Izmir Chest Hosp J* 2002;16(1):1-10 [http://igh.dergisi.org/pdf/pdf\\_IGH\\_19.pdf](http://igh.dergisi.org/pdf/pdf_IGH_19.pdf)
3. Kaptanoğlu M, Nadir A, Doğan K, Şahin E. The heterodox nature of turban pins in foreign body aspiration; the Central Anatolian experience. *Int J Pediatr Otorhinolaryngol* 2007; 71; 553-8.
4. Hasdıraz L, Biçer C, Bilgin M, Oğuzkaya F. Turban pin aspiration: nonasphyxiating tracheobronchial foreign body in young Islamic women. *Thorac Cardiovasc Surg* 2006; 54; 273-5.
5. Arsalane A, Zidane A, Atoini F, Traibi A, Kabiri EH. The surgical extraction of foreign bodies after the inhalation of a scarf pin: two cases. [Article in French] *Rev Pneumol Clin* 2009;65:293-7. [Abstract]
6. Ragab A, Ebied OM, Zalat S. Scarf pins sharp metallic tracheobronchial foreign bodies: presentation and management. *Int J Pediatr Otorhinolaryngol* 2007;71:769-73.
7. Dayioğlu E, Rahimi M, Toker A, et al. Intrabronchial foreign body. (Turkish) *TCS Surg J* 1995;3:82-5.
8. Al-Ali MA, Khassawneh B, Alzoubi F. Utility of fiberoptic bronchoscopy for retrieval of aspirated headscarf pins. *Respiration* 2007;74:309-13.
9. Türüt H, Gulhan E, Tastepe I. Unforeseen scenario in removal of a tracheobronchial foreign body. *Asian Cardiovasc Thorac Ann* 2008;16:e10-1.

10. Wiseman NE. The diagnosis of foreign body aspiration in childhood. *J Pediatr Surg* 1984;19:531-5.
11. Mehta AC, Rafanan L. Extraction of airway foreign body in adults. *J Bronchol* 2001;8:123-31.
12. Oğuzkaya F, Akçali Y, Kahraman C, Bilgin M, Sahin A. Tracheobronchial foreign body aspirations in childhood: a 10-year experience. *Eur J Cardiothorac Surg* 1998;14:388-92.
13. Pasaoglu I, Dogan R, Demircin M, Hatipoglu A, Bozer AY. Bronchoscopic removal of foreign bodies in children: retrospective analysis of 822 cases. *Thorac Cardio-vasc Surg* 1991;39(2):95-8.