



Isolated Pericardial Hydatid Cyst

¹Ümit Erkan Vurdem, ²Mehmet Fatih İnci, ³Mithat Fazlıoğlu, ⁴Arzu Taşdemir, ⁵Hakan İmamoğlu

ABSTRACT

Cardiac hydatid cyst is an uncommon disease, mostly involving the myocardium. Involvement of the pericardium or isolated pericardial hydatid cysts are extremely rare and therefore can mimic other pericardial cystic diseases. Herein we present the radiological and surgical findings of an asymptomatic isolated pericardial hydatid cyst

Key words: Hydatid cyst, magnetic resonance imaging, computed tomography, echocardiography.

İzole Perikardiyal Hidatik Kist

ÖZET

Kardiyak hidatik kist sıklıkla miyokardı tutan sık görülmeyen bir hastalıktır. Perikardiyumun tutulması veya izole perikardiyal hidatik kist son derece nadirdir ve bu yüzden diğer perikardiyal kistik hastalıkları taklit edebilir. Bu yazıda asemptomatik izole perikardiyal hidatik kistin radyolojik ve cerrahi bulgularını sunuyoruz.

Anahtar kelimeler: Hidatik kist, magnetik rezonans görüntüleme, bilgisayarlı tomografi, ekokardiyografi

INTRODUCTION

Hydatid disease is a parasitic infestation caused by *Echinococcus granulosus* larvae. It has a wide geographic distribution and humans may be infected incidentally as intermediate hosts in the parasite's life cycle. The organs most commonly affected are the liver and the lungs (1). Although cardiac involvement is known to occur, isolated pericardial disease is very rare. The clinical findings of pericardial hydatid cyst are nonspecific consisting of chest pain, dyspnea and some other cardiac complaints. Choosing the correct treatment option depends on correct diagnosis which is very difficult and needs awareness of this condition. Therefore herein we present an asymptomatic patient with a surgically proven pericardial hydatid cyst and discuss the chest X-ray (CXR), echocardiography, computed tomography (CT), and magnetic resonance imaging (MRI) findings.

¹Kayseri Education and Research Hospital, Department of Radiology, Kayseri, ²Elazığ Harput State Hospital, Department of Radiology, Elazığ, ³Kayseri Education and Research Hospital, Department of Thorax Surgery, Kayseri, ⁴Kayseri Education and Research Hospital, Department of Pathology, Kayseri, ⁵Erciyes University Medical Faculty, Department of Radiology, Kayseri

CASE

A 48-year-old woman was referred to our hospital due to external bulging of the left heart silhouette on her CXR which was noticed during a check-up examination (Figure 1). She had no complaint, and her physical examination, electrocardiography, abdominal US, cranial CT, and routine blood tests were unremarkable. On echocardiography, a multilocular cystic mass lesion with posterior acoustic enhancement was detected near the left ventricle (Figure 2). Contrast-enhanced thorax CT images performed with 10-mm thickness and index revealed a 10x10x12 cm hypodense and well-defined multilocular cystic mass lesion located in the pericardium (Figure 3). There was no other cystic lesion in the mediastinum or lung area. Thorax MRI clearly depicted the cystic mass and confirmed the internal structure of the cyst (Figure 4). The patient received albendazole treat-

Correspondence: Ümit Erkan Vurdem, Kayseri Education and Research Hospital, Department of Radiology, Kayseri/Turkey
GSM: +90 5055393633 Fax Number: 0090 352 3368857
e-mail: uervurdem@hotmail.com

Received: 12.10.2013, Accepted: 11.12.2013

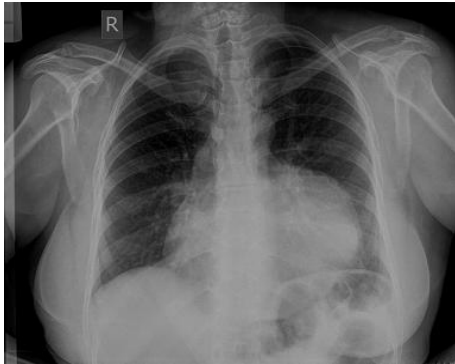


Figure 1. Anteroposterior chest radiographies showing cardiomegaly and external bulging of the left heart silhouette.

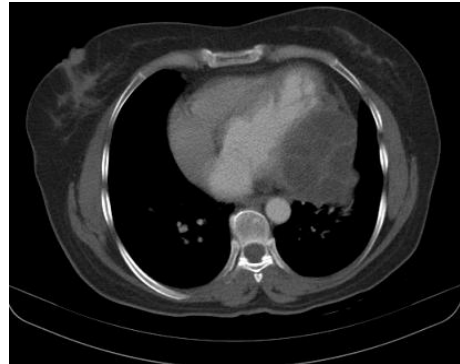

Figure 3. Chest CT scan demonstrates hypodense and well-defined multilocular cystic mass lesion located in the pericardium.

ment (30 mg/kg/day) before and after surgery. Left-sided thoracotomy was performed and the pericardial cyst, which extended to the myocardium, was removed totally after aspiration of the cystic content (Fig. 5). Pathologic examination findings revealed the diagnosis of hydatid cyst (Fig. 6). There was no residual cystic lesion in the pericardium postoperatively.

DISCUSSION

Echinococcosis is a widely known zoonosis caused by *Echinococcus granulosus*. The infection is more frequent in some areas of the world, usually caused by the larval or cyst stage of the tapeworm *Echinococcus granulosus* (2). In humans the most frequent locations of hydatid cysts are the liver (> 65% of cases), lungs (25 %) and

renal (1-5 %), but they can be seen in any location including pericardium (3). Cardiac hydatid cyst disease is uncommon, representing approximately 0.2% to 2% of all cyst-related cases. Cardiac hydatid cyst involves mostly the left ventricle (50%-70% of cases), followed by atria and the free wall of the right ventricle (30% of cases), the pericardium (15%-25% of cases), and the interventricular septum (5%-15% of cases) (4). Isolated cardiac hydatid cysts are extremely rare; only few cases have been reported (5). Clinical presentation of cardiac hydatid cysts depends on the location, size and number of cysts and presence of complications. Most patients remain asymptomatic for many years or have minor non-specific complaints, such as fever, chest pain and weakness. However, anaphylactic shock may develop due to cyst rupture into the bloodstream (6, 7).

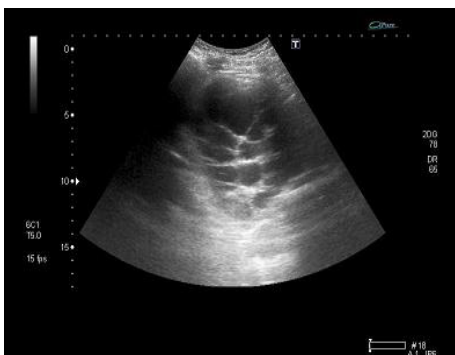


Figure 2. Echocardiography shows multilocular cystic lesions with posterior acoustic enhancement near the left ventricle.

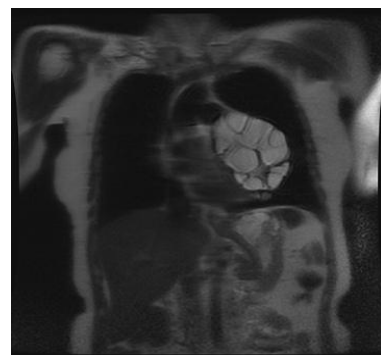


Figure 4. T2-weighted coronal spin-echo MR image shows high signal intensity multilocular cystic lesions in the pericardium.

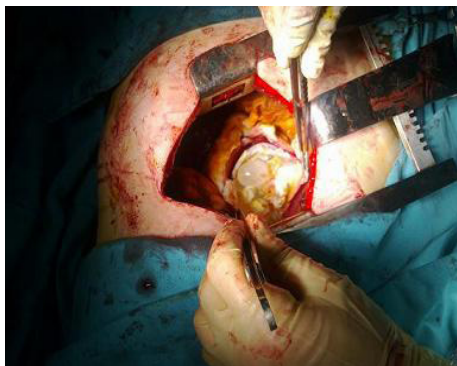


Figure 5. Operative view of the hydatid cyst after opening the pericardium.

The diagnosis of cardiopericardial hydatid cysts is difficult and the differential diagnosis consists of myocardial aneurysms, congenital pericardial cysts, pleuropericardial cysts, myocardial abscess, cystic degenerating tumors, and pericardial hematomas (6, 8). In the presence of a history of hydatid cyst any cardiopericardial mass should be considered a hydatid cyst until otherwise stated (9). Chest roentgenogram may show the lesion but it is not sufficient for characterization of the lesion. Echocardiography is the investigative procedure of choice for studying cardiopericardial hydatidosis. The signs of a hydatid cyst revealed by ultrasonography depend essentially on the stage of the disease without consideration of the affected organ. A detached membrane is the only diagnostic sign; partition of the cyst is only suggestive of the diagnosis (9). In this case, echocardiography showed a mass with a well defined edge next to the left side of the heart.

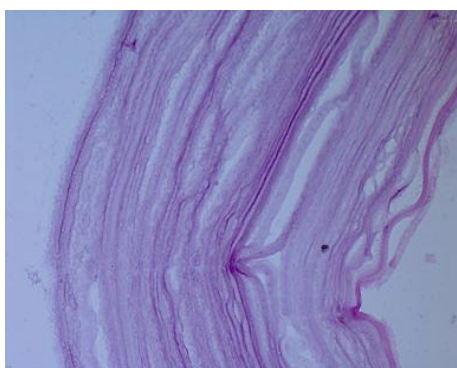


Figure 6. Pathology image of cyst revealed lamellar eosinophilic stained cuticular membran (40XH&E).

CT and MR may help to distinguish solid tumors such as myxomas or fibromas from watery tumors and intracavitary thromboses. They are also effective for searching concomitant lesions in other locations (thorax, abdominal, cerebral). They can delineate the exact site of the abnormality and thereby provide precise information for the surgeon (9,10). MR imaging may give additional information especially for the internal structure of the pericardial lesions. Lack of radiation is the most important advantage of MR over CT. Obtaining scans with different sequences may lower or eliminate the need for contrast MR provides a global view of the preoperative cardiac anatomy with high contrast between flowing blood and soft tissue, and is greatly helpful in evaluation of obese patients or patients with a chest deformity (10).

Once the diagnosis is established, surgery is the main treatment even in asymptomatic patients as sudden complications can develop. Medical treatment (e.g., albendazole and mebendazole) is necessary as a supplement to surgery, especially for disseminated cases and for prophylaxis (4). In conclusion, Echocardiography is the investigative procedure for pericardial hydatid cyst, CT and MRI are effective tools for characterization and surgery planning

REFERENCES

1. Blanton R. Echinococcosis. In: Behrman RE, Kliegman RM, Jenson HB, eds. *Nelson Textbook of Pediatrics*, 17th edn. Philadelphia: WB Saunders Company, 2004:1173-4.
2. Uysalek A, Aral A, Atalay S, Akalin H. Cardiac echinococcosis with multivisceral involvement. *Pediatr Cardiol* 1996;17:268-70.
3. Gürlek A, Dagalp Z, Ozyurda U. A case of multiple pericardial hydatid cysts. *Int J Cardiol* 1992;36:366-8.
4. Urbanyi B, Rieckmann C, Hellberg K, et al. Myocardial echinococcosis with perforation into the pericardium. *J Cardiovasc Surg* 1991;32:534-8.
5. Vural M, Sayin B, Pasaoglu L, Koparal S, Elverici E, Dede D. Isolated pericardial hydatid cyst in an asymptomatic patient: a remark on its radiologic diagnosis. *Clin Imaging* 2007 Jan-Feb;31(1):37-9.
6. Birincioğlu CL, Bardakci H, Küçüker SA, et al. A clinical dilemma: Cardiac and pericardiac echinococcosis. *Ann Thorac Surg* 1999;68:1290-4.
7. De Martini M, Nador F, Binda A, Arpesani A, Odero A, Lotto A. Myocardial hydatid cyst ruptured into the pericardium: Crosssectional echocardiographic study and surgical treatment. *Eur Heart J* 1988;9:819-24.

8. *Malamou-Mitsi V, Pappa L, Vougiouklakis T, et al. Sudden death due to an unrecognized cardiac hydatid cyst. J Forensic Sci 2002;47:1062-4.*
9. *Thameur H, Abdelmoula S, Chenik S, et al. Cardiopericardial Hydatid Cysts. World J. Surger 2001;25:58-67.*
10. *Sakarya ME, Etlik O, Sakarya N, et al. MR findings in cardiac hydatid cyst. Clin. Imagin 2002;26:170-2.*