

Recurrence of Primary Cardiac Rhabdomyosarcoma without Methastasis Two Years After Surgery

Hakki Simsek¹, Musa Sahin², Hasan Ali Gumrukcuoglu³, Mustafa Tuncer³, Yilmaz Gunes³

ABSTRACT

Primary malignant cardiac tumors are rare. Rhabdomyosarcoma is the most common of these lesions. These tumors usually arise from the ventricular walls. They sometimes arise from the atrial walls and mimic atrioventricular valve stenosis. A case of recurrence of primary cardiac rhabdomyosarcoma without metastasis to other organs in a 34 year old woman is presented. The tumor arose from the posterior wall of the left atrium and extended to the posterior mitral valve leaflet. Histopathology confirmed recurrence of the cardiac rhabdomyosarcoma. Although cardiac rhabdomyosarcomas are highly lethal, operation indicated. Clarify diagnosis, relieve symptoms and improve survive intracardiac mass must be excision as as extensively as possible in these cases in order to prevent recurrence of tumor.

Key words: Cardiac neoplasm, rhabdomyosarcoma, recurrence

Cerrahiden İki Yıl Sonra Metastaz Olmaksızın Primer Kardiyak Rabdomyosarkomun Rekürrensi

ÖZET

Kalp kökenli malign tümörler nadir olarak görülmektedir. Sıklıkla ventriküler duvardan köken alan rabdomyosarkoma en sık karşılaşılan kalp kökenli malign tümördür. Rabdomyosarkoma nadiren atriyum duvarından köken alır ve atriyovanküler kapak darlığını taklit edebilir. Bu yazıda kalp kökenli rabdomyosarkom nedeniyle operasyon geçiren 34 yaşında bir kadın hastada diğer organlarda metastaz olmaksızın görülen rabdomyosarkoma rekürrensi sunuldu. Tümör sol atriyumun posteriyor duvarından köken almaktaydı ve mitral kapağın posteriyor kapakçığına doğru uzanıyordu. Hasta tekrar opere edildi kitlenin histopatolojik tanısı rekürren rabdomyosarkomu doğruladı. Kardiyak rabdomyosarkomun prognozu kötü olmasına rağmen teşhisin doğrulanması semptomların azaltılması ve hayat beklentisinin uzaması için cerrahi müdahale endikedir. Tümörün rekürrensini önlemek için mümkün olduğu kadar geniş cerrahi uygulanmalıdır.

Anahtar kelimeler: Kalp kanserleri, rabdomyosarkom, nüks

INTRODUCTION

Cardiac rhabdomyosarcoma (CR) accounts for almost 20% of all primary malignant neoplasms of the heart (1,2). These tumors usually arise from the ventricular walls, and they frequently interfere with valvular motion because of their intracavitary bulk (3), however sometimes are located in the atrial walls and mimic atrioventricular valve stenosis (4). CR usually present with symptoms related to cardiac location of the mass. Transthoracic and

transesophageal echocardiography (TEE) can diagnose the presence of cardiac mass. But these imaging techniques rarely define true nature of mass, especially when it is located in the atria (2). Only histopathology can confirm the nature of the cardiac lesion. CR is highly lethal and prognosis is poor. However, surgery is indicated for malignant cardiac neoplasms to relieve cardiac symptoms and to prolong patient survival. Subsequent postoperative chemotherapy or radiotherapy is necessary (3).

¹Osmaniye State Hospital, Cardiology Department, Osmaniye, Turkey, ²Bitlis State Hospital, Cardiology Department, Bitlis, Turkey, ³Yuzuncu Yil University, Faculty of Medicine, Cardiology Department, Van, Turkey.

Correspondence: Hasan Ali Gumrukcuoglu
Yuzuncu Yil University, Faculty of Medicine, Cardiology Department, Van, Turkey.
Tel: +905347151669 Fax no: +90432 2168352
e-mail: hasanalig80@yahoo.com

Received: 21.08.2010, Accepted: 14.06.2011

We report a case of primary cardiac rhabdomyosarcoma that presented with recurrence in the same location and survived for two years without methastasis after surgical resection.

CASE

A 34 year old woman was admitted to the hospital because of exertional dyspnea palpitations and peripheral edema for four days. The patient said that she was operated due to cardiac mass two years ago and subsequent radiotherapy and chemotherapy was performed. Her previous reports demonstrated a pleomorphic type rhabdomyosarcoma arising from the posterior wall of the left atrium extending to the posterior mitral valve leaflet. The mass was excised with mitral valve protection and metastasis had not been determined in neither the thoracoabdominal computerized tomography (CT) nor positron emission tomography (PET) scans performed after operation. Upon physical examination, the patient was dyspneic at rest and moderate pretibial edema was present. Arterial pressure was 100/70 mmHg, heart rate was 104 beat/min. Peripheral arterial pulses were normal. On auscultation no murmur was heard. The electrocardiogram revealed sinus tachycardia. Chest radiography was normal. Transthoracic 2-D echocardiography (TTE) revealed a 3x3 cm diameter left atrial mass with irregular borders (Figure 1) and moderate mitral stenosis (mitral valve area: 1.5 cm², and peak/mean gradients across the mitral valve assessed by continuous wave Doppler were: 20/9 mmHg). This mass was attached to the posterior wall of the left atrium, mimicking a large thrombus, and it extended to the posterior mitral valve leaflet as signated her prior reports. This lesion was evaluated as a recurrence of CR according to history and findings. CT and PET scans performed for evaluation of methastasis to other organs didn't show any methastasis again and referred the patient to cardiovascular surgery. The mass was excised and the mitral valve posterior leaflet was resected and fixed by way of its plasticity with pericardium in the second operation. The patient was given the second subsequent radiotherapy and chemotherapy.

Pathological examination confirmed the diagnosis of recurrent CR. TTE performed two months after second operation revealed reconstruction of the posterior wall of the left atrium with pericardium and immobility of mitral valve posterior leaflet due to its plasticity with pericar-

dium. Neither tissue masses in the left atrium nor mitral valve stenosis was seen (Figure 2).

DISCUSSION

Primary malignant tumors of the heart are rare. Holley et al. (1) reported they occur with the frequency of 0.001-0.28% of which 75% are benign and 25% are malignant in origin (1). Cardiac rhabdomyosarcoma accounts for almost 20% of all primary malignant neoplasms of the heart. However, Blondeau (5) has reported the frequency of malignant tumors as 10%. Cardiac rhabdomyosarcomas are rare tumors (6) accounting for about 4% of primary cardiac neoplasm, although this prevalence has not been commonly reported; in a large series of 75 primary cardiac sarcomas, none of them were found to be a rhabdomyosarcoma (3).

Cardiac rhabdomyosarcoma is characterized with intraluminal growth, expressed invasion in myocardium and cardiac valves and rapid obstruction of the lumen. Although CR usually arise from the ventricular walls, in adult patients sometimes arise from the atrial walls and cause atrioventricular stenosis as in our case (4). In those cases, the tumor is usually given a presumptive diagnosis of thrombus or myxoma (1,4). For the revealing of intracardiac tumors echocardiography and magnetic resonance imaging are valuable methods. Transesophageal echocardiography (TEE) is superior to transthoracic echocardiography as it provides anatomical depicting of the mass (7). It allows to distinguish tumors from thrombi and extra cardiac mass lesions (8). Magnetic resonance (MR) also provides precise description of localization and extent of the tumor. Cardiac MR could not be performed in this case due to its not available.

Cardiac rhabdomyosarcoma is very aggressive, like other sarcomas, and often presents as acute heart failure. However, clinical presentation differs in accordance with the location of the mass. By the time cardiac symptoms become evident, metastatic lesions are usually diffuse. Although survival of up to 5 years has been reported (9), prognosis is very poor: patients usually survive less than 1 year, in spite of excision of the primary tumor and subsequent radiation and chemotherapy. Nevertheless, surgery is usually necessary to elucidate the diagnosis and alleviate symptoms. In our case since the mass nearly attached to posterior leaflet of mitral valve and prevented its motion, the unusual presentation of a rapidly evolving

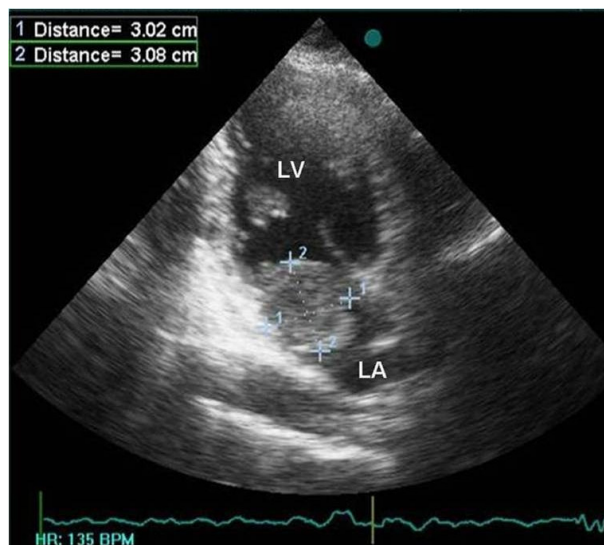


Figure 1. Left atrial mass leading to mitral stenosis.

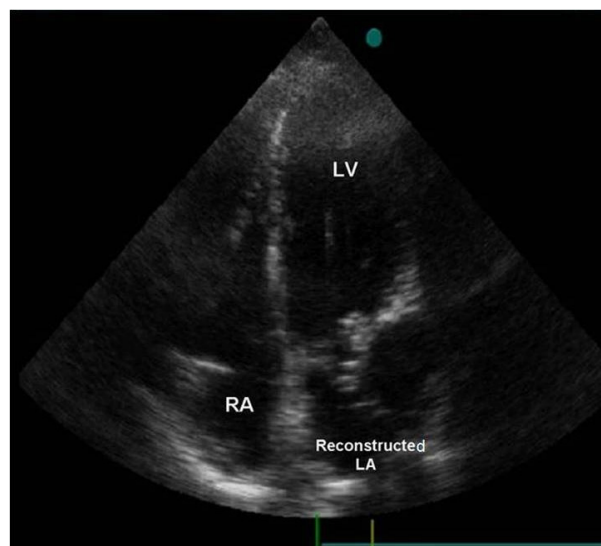


Figure 2. Absence of any tissue masses in the reconstructed left atrium.

mitral valve stenosis caused early symptoms which let us to detect the mass without metastasis to other organs.

Although CR is highly lethal, we conclude on the basis of our experience that operation is indicated and excision of the intracardiac mass must be performed as extensively as possible in these cases in order to prevent recurrence of tumor, provide palliation and improve survival.

REFERENCES

- Holley DG, Martin GR, Brenner JI, et al. Diagnosis and management of fetal cardiac tumors: a multicenter experience and review of published reports. *J Am Coll Cardiol* 1995;26:516-20
- Castorino F, Masiello P, Quattrocchi E, et al. Primary Cardiac Rhabdomyosarcoma of the Left Atrium An Unusual Presentation. *Tex Heart Inst J* 2000;27:206-8
- Burke AP, Cowan D, Virmani R. Primary sarcomas of the heart. *Cancer* 1992;69:387-95.
- Villasenor HR, Fuentes F, Walker WE. Left atrial rhabdomyosarcoma mimicking mitral valve stenosis. *Tex Heart Inst J* 1985;12:107-10.
- Blondeau P. Primary cardiac tumors - French studies of 533 cases. *Thorac Cardiovasc Surg* 1996;38:192-5.
- Hui KS, Green LK, Schmidt WA. Primary cardiac rhabdomyosarcoma: definition of a rare entity. *Am J Cardiovasc Pathol* 1988;2: 29.
- Aru GM, Falchi S, Cardu G, et al. The role of transesophageal echocardiography in the monitoring of cardiac mass removal: a review of 17 cases. *J Card Surg* 1993 Sep;8:554-7.
- Reeder GS, Khandheria BK, Seward JB, et al. Transesophageal echocardiography and cardiac masses. *Mayo Clin Proc* 1991; 66:1101-9.
- Miralles A, Bracamonte L, Soncul H, et al. Cardiac tumors: clinical experience and surgical results in 74 patients. *Ann Thorac Surg* 1991;52:886-95.