

The Radiological Evaluation of External Ophthalmoplegia: Tolosa-Hunt syndrome

Hatice Gül Hatipoğlu¹, Hasan Ali Durmaz², Onur Ergun², Semra Duran¹, Mehtap Cavuşoğlu¹, Deniz Ciliz¹, Enis Yüksel¹

ABSTRACT

The Tolosa-Hunt syndrome is recurrent painful ophthalmoplegia due to nonspecific cavernous sinus inflammation. The documented incidence is one to two cases per million and bilaterality is even rarer. Delay in diagnosis might lead to permanent cranial nerve damage. Our purpose in this study is to discuss clinical and radiological features of the disease. We reported two patients whom presented with external ophthalmoplegia. The preliminary clinical diagnosis was ophthalmoplegic migraine. The primary radiological evaluation including cranial CT, cerebral angiography, magnetic resonance venography were all in normal limits. Finally MR imaging was performed which demonstrated the disease in the cavernous sinus region. We believe this article will serve not only to radiologists but a broad group of specialists including neurologists, otolaryngologists, internal medicine physicians dealing with cases of external ophthalmoplegia.

Key words: Tolosa-Hunt syndrome, MRI, ophthalmoplegia, cavernous sinus, CT

Eksternal oftalmoplejili bir olgunun radyolojik değerlendirilmesi: Tolosa-Hunt sendromu

ÖZET

Tolosa-Hunt sendromu kavernöz sinüsün spesifik olmayan enflamasyonuna bağlı olarak gelişen tekrarlayan ağrılı oftalmoplejidir. Görülme sıklığı milyonda bir veya iki vaka olarak belirtilirken bilateral görülmesi ise çok daha nadirdir. Tanıda olası gecikme kalıcı kranial sinir hasarına yol açabilir. Biz bu olgu sunumunda bu hastalığın klinik ve radyolojik özelliklerini tartışmayı hedefleyerek eksternal oftalmopleji ile prezente olan iki olgu sunmayı amaçladık. Klinik ön tanısı oftalmoplejik migren olan bu iki hastanın kranial bilgisayarlı tomografi, serebral anjiyografi ve manyetik rezonans venografiden oluşan radyolojik değerlendirilmesi normal sınırlardaydı. Hastaya son olarak çekilen kranial manyetik rezonans ile kavernöz sinüs bölgesinde hastalık gösterilerek tanı konuldu. Biz bu yazının sadece radyologlar için değil, eksternal oftalmopleji vakaları ile karşılaşabilen nöroloji, kulak burun boğaz ve dahiliye gibi bir çok uzmanlık dalı klinisyenleri için faydalı olacağını düşünmekteyiz.

Anahtar kelimeler: Tolosa-Hunt sendromu, MRG, oftalmopleji, Kavernöz sinüs, BT

INTRODUCTION

Tolosa-Hunt syndrome (THS) is a rare disease with a documented incidence of one to two cases per million (1). The bilaterality is even rarer with an incidence of 4.1-5 percent of all cases (1). It is non-specific granulomatous inflammation of the cavernous sinuses which

results in external ophthalmoplegia. The disease is reported to extend into superior orbital fissure and orbita as well (1,2). The etiology is yet to be explored. The list of diseases which result in external ophthalmoplegia is broad and need to be excluded prior to final diagnosis. It includes trauma, tumors, vascular pathologies like aneurysm and fistula, infections, diabetic ophthal-

¹Ankara Numune Training and Research Hospital, Department of Radiology, Ankara, Turkey, ²Ankara Dışkapı Yıldırım Beyazıt Training and Research Hospital, Department of Radiology, Ankara, Turkey

Correspondence: Onur Ergun
Address: Dışkapı Yıldırım Beyazıt Eğitim ve Araştırma Hastanesi, İrfan Baştuğ cad. Dışkapı Ankara
Telephone: +90 312 5962000 Fax: +90 312 3186690
Mobile phone: +90 532 6954040 e-mail: onurergun@yahoo.com

Received: 19.07.2013, Accepted: 05.11.2013

moplegia and ophthalmoplegic migraine among others (2). The diagnostic evaluation of those patients include haematological tests, cerebrospinal fluid studies, imaging studies and biopsy.

In both cases that we presented, the preliminary diagnosis was ophthalmoplegic migraine which lead to a delay in the treatment. Therefore, our purpose in this study is to discuss the importance of magnetic resonance imaging in diagnosing the aetiology of patients with external ophthalmoplegia for accurate and prompt treatment of cases with Tolosa-Hunt syndrome. We believe this article will serve not only to radiologists but also a broad group of specialists including neurologists, otolaryngologists, and internal medicine physicians dealing with cases of external ophthalmoplegia.

CASE 1

A 42-year-old man presented with right sided headache which has begun 45 days ago. His symptoms progressed into severe pulsatile headache accompanied by photophobia, ptosis and blurring of vision in the last week. Cranial CT exam and cerebral digital subtraction angiography were within normal limits. The clinical preliminary diagnosis was ophthalmoplegic migraine. There was no history of prior attacks and migraine in the family. There was no response to the treatment of

migraine. The patient was transferred to our hospital. The neurological exam demonstrated ptosis, dilatation of the right pupil, hypoesthesia of ophthalmic, maxillary and mandibular branches of the trigeminal nerve on the right side. There was partial restriction in the eye motions when looking into outside and upward. The eye movements were free on the left side. There was no facial asymmetry. The laboratory findings were in normal limits. Gadolinium-enhanced MRI exam of the brain and pituitary gland were obtained. There was expansion of the right cavernous sinus with signal change isointense to muscle on T1 (Figure 1A) and T2-weighted (Figure 1B) images. There was intense heterogenous enhancement after intravenous contrast administration (Figure 1C). The findings were found to be consisted with Tolosa-Hunt Syndrome. A mild heterogenous signal change was also noted in the cavernous sinus around the left internal carotid artery. Adenohypophysis was normal. The patient was given 1 g prednol intravenously. Then, 80 mg / day oral prednol was started. The headache of the patient significantly reduced in 48-72 hours. Partial improvement in the eye movements was observed at that time. Within a week ophthalmoplegia disappeared. The steroid dose was decreased in 2 months, and stopped. There was no relapse in 1.5 year follow-up.

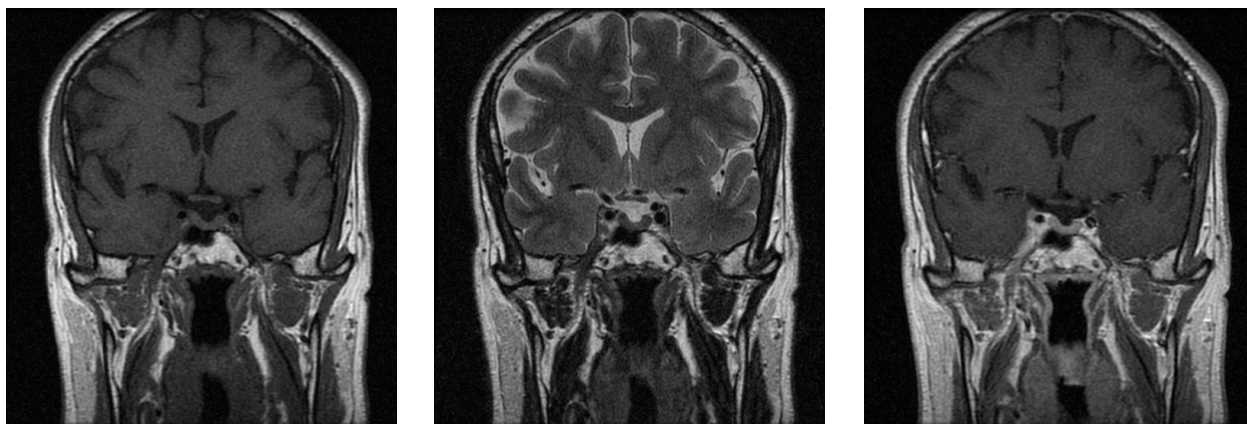

Figure 1. There is expansion of the right cavernous sinus with signal change which is isointense to muscle on T1 (Figure 1A) and T2-weighted (Figure 1B) images. There is prominent heterogenous enhancement after intravenous contrast administration (Figure 1C). The cavernous segment of the right internal carotid artery is narrowed. Please note some mild heterogeneity in the cavernous sinus around the left internal carotid artery.

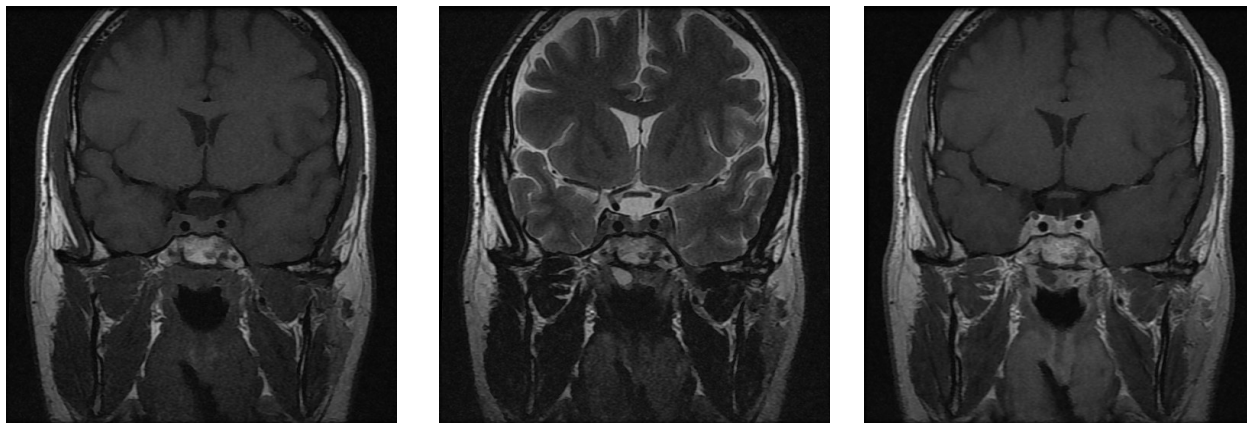


Figure 2. There is expansion of both cavernous sinuses which is more prominent on the left side. The signal change is isointense to muscle on T1 (Figure 2A) and T2-weighted (Figure 2B) images. There is prominent heterogenous enhancement after intravenous contrast administration (Figure 2C). The cavernous segment of the left internal carotid artery is narrowed. Please note some mild expansion and signal change in the right cavernous sinus compared to the other side.

CASE 2

A 36-year old male presented with headache and numbness on the left side of the head in the last month which was followed with ptosis, blurred and double vision in the last two weeks. There was no history of migraine type headache in the patient and family. The neurological exam demonstrated ptosis of the left eye. Eye movements were restricted to outside. The fundus exam was normal. The light reflex was normal. The clinical findings were consistent with external progressive ophthalmoplegia on the left side. The ophthalmological exam was in normal limits on the right side. The laboratory exam was normal except an increase in IGF-1 level (IGF-1: 765 ng / ml). Cranial CT and cerebral MR venography exams obtained in the emergency room were in normal limits. A gadolinium-enhanced MRI exam of the brain and pituitary gland was obtained. There was expansion of both cavernous sinuses with signal change isointense to muscle on T1 (Figure 2A) and T2-weighted (Figure 2B) images which was more prominent on the left side. There was intense heterogenous enhancement of both cavernous sinuses after intravenous contrast administration. The cavernous segment of the left internal carotid artery was narrowed (Figure 2C). The findings were found to be consistent with Tolosa-Hunt syndrome. The patient was given 250 mg prednol intravenously. Then, 80 mg / day oral prednol was started. The head-

ache was significantly reduced in 48 hours. Within 2 weeks, ophthalmoplegia disappeared. The treatment of steroid was decreased in 3 months and stopped. There was no relapse in 1 year follow-up.

DISCUSSION

Tolosa was first to report a patient with total ophthalmoplegia in 1954 (3). The diagnostic work included cerebral angiography which demonstrated narrowing of the intracavernous portion of the internal carotid artery. The histopathological exam revealed a low-grade non-specific granulomatous inflammation of the cavernous sinus and adventitia of the carotid artery. Later, Hunt et al documented a group of six patients with ophthalmoplegia which was resolved by corticosteroid administration in 1961 (4). The clinical criteria of the disease was outlined for the first time. The histopathological exam revealed proliferation of fibroblasts, lymphocytes and plasma cells within the adventitia of the vessels. It was the article by Smith and Taxdal who gave the eponym Tolosa-Hunt syndrome to the disease entity characterised with painful ophthalmoplegia due to idiopathic granulomatous inflammation of the cavernous sinus in 1966 (5).

THS constitutes 2.9-3.4% of the cases with painful ophthalmoplegia (6). There is no age or sex predilection (1).

The disease is usually unilateral with no predisposition for right or left cavernous sinus (6). It has an age onset ranging from 3-75 years. The diagnostic criteria recently revised by the International Headache Society includes demonstration of granuloma by MRI or biopsy in addition to others: one or more episodes of unilateral orbital pain persisting for weeks if untreated; paresis of one or more of the third, fourth and/or sixth cranial nerves and/or; paresis coincides with the onset of pain or follows it within 2 weeks; pain and paresis resolve within 72h when treated adequately with corticosteroids and other causes have been excluded (7, 8). The 3rd cranial nerve is involved in 85% of the cases, the 6th cranial nerve in 70% of the cases, the first branch of trigeminal nerve in 30% of the cases, and the 4th cranial nerve in 29% of the cases (6, 9).

Although, both of our patients didn't reveal pathological findings, CT might demonstrate enlarged cavernous sinus with a concave lateral margin. The other findings that have been reported are effacement of Meckel cave, erosion of the sella turcica, segmental narrowing of the cavernous carotid artery and occlusion of the superior ophthalmic vein (10, 11). However, the majority of patients with THS have been reported to be normal on CT (11, 12). Cerebral angiography is an invasive technique, it was commonly used in diagnosis prior to CT and MRI. The findings include narrowing of the cavernous segment of the internal carotid artery, occluded superior ophthalmic vein and nonvisualization of the cavernous sinus (11, 13). Narrowing of the petrous segment of the internal carotid artery was also reported (14). Plain films might show erosion of the sella turcica (13, 15). Orbital phlebography is reported to be abnormal in up to 50% of the cases, but the specificity is low and it is an invasive technique (16, 17). Histopathological diagnosis is not preferred due to the proximity to the vital structures. Immediate steroid therapy will prevent the permanent damage to the involved cranial nerves. Therefore, the diagnosis shouldn't be delayed (18). Advantages of MRI compared to CT include multiplanar imaging of cavernous sinus, absence of bone artefacts in the sellar region, absence of radiation exposure and lesser side effects of gadolinium (16). The findings include isointense signal with muscle on short TR/TE images and isointense signal with fat on long TR/TE images on MRI (13). The signal changes was demonstrated in cavernous sinuses in both patients. The signal intensity could vary from hypointensity (four patients), to hyper-

intensity (two patients) and intermediate signal (one patient) in a study by Jain et al which included seven patients (19). The isointense signal intensity might support the opinion which classifies both pseudotumor of the orbit and THS in the same disease process (20). The lesion will enhance intensely after intravenous gadolinium administration (21). The granulomas might give a heterogeneous appearance. When contrast was administered dynamically, the lesions would enhance slowly and gradually in the subsequent images (16). Haque et al demonstrated the sensitivity of dynamic MR imaging for THS as 83,3%, while the specificity was 100%. But the major limitation of their study was small sample size (16). MRI might show total or partial regression of the findings after corticosteroid administration on follow-up exams (6, 13, 16). This is an important diagnostic criterion to put the definitive diagnosis of THS and to differentiate it from other cavernous sinus lesions which simulate the disease clinically and radiologically (7). MR angiography would support the diagnosis by demonstrating the narrowing of the cavernous portion of the internal carotid artery (22). A small number of patients might have a normal initial MRI examination and the following studies could demonstrate the disease (18).

Steroid responsive causes of external ophthalmoplegia include not only THS but also metastases, ophthalmoplegic migraine, lymphoma, sarcoidosis, Wegener's granulomatosis, and carotid-cavernous fistula. Due to the high nuclei to cytoplasm ratio diseases like meningioma and lymphoma would present intermediate signal on T2-weighted images. However, sarcoidosis, metastasis and lymphoma often have other systemic and neurological symptoms. Meningiomas, diabetic ophthalmoplegia will not respond to steroid therapy. Aneurysms, cavernous sinus thrombosis, carotid-cavernous fistulae and giant cell arteritis can be detected with angiography or MRI. Tumors of the nasopharynx and sinusitis complications could be differentiated from THS on CT and MRI. (1, 6, 13, 16, 21) Orbital-periorbital pain and paresis resolve within 72h if treated adequately with corticosteroids (8). In some cases the therapy relieves the cranial nerve dysfunctions within 6-8 weeks (6) and residual nerve palsies rarely persist (23). The disappearance of symptoms following the systemic corticosteroid treatment may precede the normalization of neuroradiological studies by weeks or even several months (6).

As a conclusion, magnetic resonance imaging shows high sensitivity in the detection and differential diagnosis of

cavernous sinus pathologies for recognizing Tolosa-Hunt Syndrome. Therefore, in order to prevent a delay in diagnosis, it should be considered as the initial diagnostic imaging modality in this group of patients presenting with external ophthalmoplegia.

REFERENCES

- Iaconetta G, Stella L, Esposito M, Cappabianca P. Tolosa-Hunt syndrome extending in the cerebellopontine angle. *Cephalalgia* 2005; 25:746-50.
- Lachanas VA, Karatzias GT, Tsitiridis I, Panaras I, Sandris VG. Tolosa-Hunt syndrome misdiagnosed as sinusitis complication. *J Otol and Laryngol* 2008; 12:97-9.
- Tolosa E. Periartritic lesions of the carotid siphon with the clinical features of a carotid infraclinoid aneurysm. *J Neurol Neurosurg Psychiatry* 1954; 17: 300-2.
- Hunt WE, Meagher JN, LeFever HE, Zeman W. Painful ophthalmoplegia. Its relation to indolent inflammation of the cavernous sinus. *Neurology* 1961; 11:56-62.
- Smith JL, Taxdal DSR. Painful ophthalmoplegia. The Tolosa-Hunt syndrome. *Am J Ophthalmol* 1966; 61:1466-72.
- Cakirer S. MRI findings in Tolosa-Hunt syndrome before and after systemic corticosteroid therapy. *Eur J Radiol* 2003; 45:83-90.
- Kóbor J, Vörös E, Deák A. Magnetic resonance imaging in Tolosa-Hunt syndrome. *Eur J Pediatr* 2004; 163:753-4.
- Headache Classification Sub-Committee of the International Headache Society. The International classification of headache disorder, 2nd edn. *Cephalalgia* 2004; 24:1-160.
- Tessitore E, Tesitore A. Tolosa-Hunt syndrome preceded by facial palsy. *Headache* 2000; 40:393-6.
- Kwan ES, Wolpert SM, Hedges TR 3rd, Laucella M. Tolosa-Hunt syndrome revisited: not necessarily a diagnosis of exclusion. *AJR Am J Roentgenol* 1988; 150:413-8.
- Aron-Rosa D, Doyon D, Salamon G, Michotey P. Tolosa-Hunt syndrome. *Ann Ophthalmol* 1978; 10: 1161-8.
- Van Dalen JTW, Bleeker GM. The Tolosa-Hunt syndrome. *Doc Ophthalmol* 1977; 44:167-72.
- Yousem DM, Atlas SW, Grossman RI, Sergott RC, Savino PJ, Bosley TM. MR imaging of Tolosa-Hunt syndrome. *AJR Am J Roentgenol* 1990; 154:167-70.
- Odabaşı Z, Gökçil Z, Atilla S, Pabuşçu Y, Vural O, Yardim M. The value of MRI in a case of Tolosa-Hunt syndrome. *Clin Neurol Neurosurg* 1997; 99:151-4.
- Polsky M, Janicki PC, Gunderson CH. Tolosa-Hunt syndrome with sellar erosion. *Ann Neurol* 1979; 6:129-31.
- Haque TL, Miki Y, Kashii S, et al. Dynamic MR imaging in Tolosa-Hunt syndrome. *Eur J Radiol* 2004; 51:209-17.
- Hannerz J, Ericson K, Bergstrand G. Orbital phlebography in patients with Tolosa-Hunt's syndrome in comparison with normal subjects. *Acta Radiol Diagn* 1984; 25:457-63.
- Aktan S, Aykut C, Erzen C. Computed tomography and magnetic resonance imaging in three patients with Tolosa-Hunt syndrome. *Eur Neurol* 1993; 33:393-6.
- Jain R, Sawhney S, Koul RL, Chand P. Tolosa-Hunt syndrome: MRI appearances. *J Med Imaging Radiat Oncol* 2008; 52:447-51.
- Bosch J, Ortega-Aznar A, Tintore M et al. Hypertrophic pachymeningitis. A review of the histories of two cases and pathological relationship with the Tolosa-Hunt syndrome and the orbital pseudotumor. *Rev Neurol* 2000; 3:946-51.
- Zournas C, Trakadas S, Kapaki E, et al. Gadopentetate dimeglumine-enhanced MR in the diagnosis of the Tolosa-Hunt syndrome. *AJNR Am J Neuroradiol* 1995; 16:942-4.
- Ozawa T, Minakawa T, Saito A, Yoneoka Y, Yoshiruma J, Arai H. MRA demonstration of 'Periarteritis' in Tolosa-Hunt syndrome. *Acta Neurochir (Wien)* 2001;143:309-12.
- Kline LB, Hoyt WF. The Tolosa-Hunt syndrome. *J Neurol Neurosurg Psychiatry* 2001; 71:577-82.