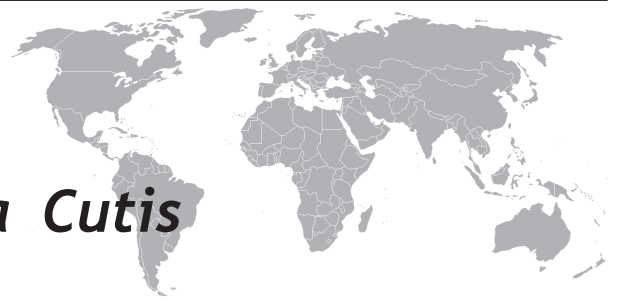



Tuberculosis Verrucosa Cutis

Cihangir Aliğaoğlu¹, Mustafa Atasoy², Ali İhsan Güleç³,
Şevki Özdemir², Teoman Erdem², R. İsmail Engin²

¹ Düzce University, Faculty of Medicine, Department of Dermatology, Düzce, Turkey

² Atatürk University, Faculty of Medicine, Department of Dermatology, Erzurum, Turkey

³ Osmaniye State Hospital, Department of Dermatology, Osmaniye, Turkey

Eur J Gen Med 2009; 6(4): 268-273

ABSTRACT

Tuberculosis verrucosa cutis is a paucibacillary form of cutaneous tuberculosis caused by exogenous re-infection in previously sensitized individuals. The arms and feet were involved in three cases. Gluteal area was involved in one case. Ziehl-Neelsen and periodic acid-Schiff stains did not demonstrate any acid-fast bacilli. Cultures were positive for Mycobacterium tuberculosis except one case. Lesions of tuberculosis verrucosa cutis improved after anti-tuberculous therapy. There were no active organ and other skin tuberculosis.

Key word: *Tuberculosis verrucosa cutis, different area involvement, rural area.*

INTRODUCTION

Tuberculosis verrucosa cutis (TBVC) is a paucibacillary form of cutaneous tuberculosis caused by exogenous re-infection in previously sensitized individuals. Inoculation occurs at sites of minor wounds or abrasions, and rarely from the patient's own sputum. TBVC usually occurs on the hands in adults and on the lower extremities in children (1). In western countries TBVC is a very rare form of cutaneous tuberculosis, but in the Asian subcontinent it may be quite common (2). TBVC takes important and superior part in the spectrum of cutaneous tuberculosis. A patient sensitized to Mycobacterium tuberculosis begins to develop an immune response, which may sometimes result in a disorder in the spectrum of cutaneous tuberculosis. The spectrum varies from moderate to high cell-mediated immunity and contains lupus vulgaris, scrofuloderma and tuberculosis cutis orifacialis. TBVC is arranged in proper order between lupus vulgaris and scrofuloderma (3). We report here four TBVC cases, which were localized in several parts of the body.

Correspondence:

Güven Sunam, MD

Mustafa Atasoy, MD

Atatürk Üniversitesi Postanesi P.K: 2
25171 Erzurum-Turkey

Phone: +90 442 2360738

Fax: +90 442 2361301

E-mail: mustafaatasoy@hotmail.com

CASE 1

A 40-year-old man was admitted to our clinic with the complaints of verrucous lesions over the third finger, which existed during the last 3 years. It started as a painless papule after a trauma. This lesion had enlarged slowly over the last 3 years. Bacillus of Calmette and Guerin (BCG) vaccination scar was identified on the left deltoid. It failed to respond to antimicrobial therapy over a 6-week period. His personal and family histories were not contributory.

Dermatological examination revealed a 1-3 cm erythematous-verrucous plaque on the third finger. It was painless, had an irregular outline, a horny surface and was firm in consistency (Figure 1A). The histopathology showed a granulomatous infiltration mainly of the upper dermis with many giant cells but no sign of necrosis. There was epidermal hyperplasia and orthokeratosis (Figure 1B). *M. tuberculosis* was cultured from the biopsy specimen after five weeks.

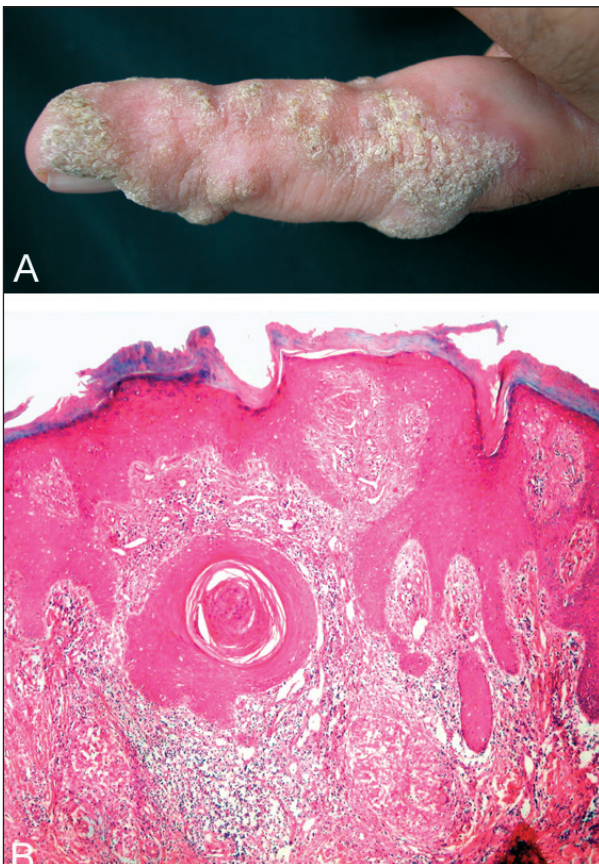


Figure 1A. Erythematous-verrucous plaque on the third finger. **1B.** Epidermal hyperplasia, orthokeratosis, and granulomatous infiltration mainly of the upper dermis (H&Ex4).

CASE 2

A 45-year-old male was admitted to our clinic with the complaint of verrucous lesions over the right forearm, which existed during the last 5 years. It started as a painless papule on the site of a trauma. This lesion gradually increased in size over several months and intermittently got tender, discharging yellow colored pus. BCG vaccination scar was identified on the left deltoid. Her personal and family histories were not contributory. It failed to respond to topical antibiotic ointment therapy over a 3-week period.

Dermatological examination revealed a 2-3 cm verrucous plaque on the right forearm. The top of the plaque was irregular and had alternating elevations and depressions (Figure 2A). An incisional biopsy specimen of the plaque showed a dermal granulomatous inflammation consisting of lymphocytes, epithelioid and Langhans' giant cells. There was epidermal hyperplasia and orthokeratosis. However, no caseating necrosis was present (Figure 2B). *M. tuberculosis* was cultured from the biopsy specimen after six weeks.

CASE 3

A 55-year-old female was admitted to our clinic with the complaint of long-standing verrucous lesions over the left forearm and right foot that existed during the last 10 years. It started as a painless papule on a traumatic site. These lesions gradually enlarged over a 10-year period. BCG vaccination scar was not present. Her personal and family histories were not contributory. No diagnosis had been established and no treatment had been given throughout the last 10 years.

4-5 lesions that had verrucous manner were detected on left hand. However, a plaque on right knee which was ellipsoid, verrucous manner had a central part healed completely. Also 2-3 verrucous nodular lesions were seen on upper part of right knee, (Figure 3). The entire dermis was composed of non-caseous granulomatous inflammation, which contains epithelioid histiocytes, lymphocytes, and large numbers of Langhans type giant cells. There was epidermal hyperplasia and orthokeratosis (Figure 3). The culture did not yield *M. tuberculosis*.

CASE 4

A 32-year-old woman had slowly enlarging, painless, and verrucous plaques on the right buttocks. The first lesion had appeared approximately 9 years earlier on

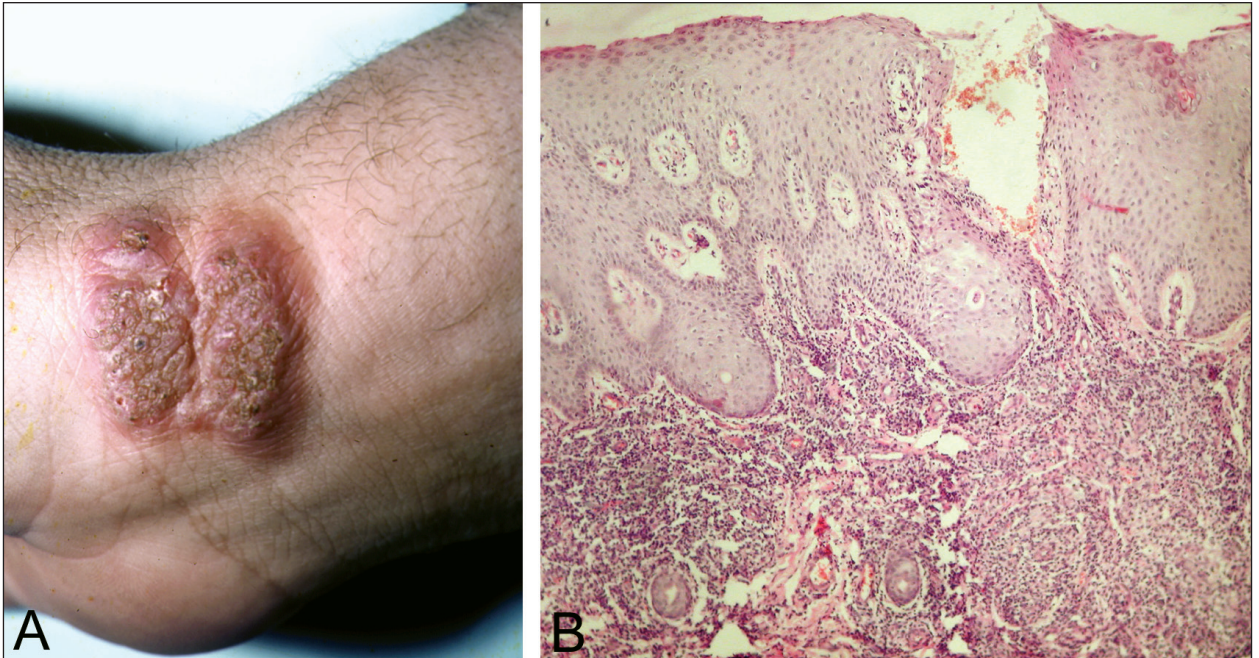


Figure 2A. Verrucous plaque on the right forearm. **2B.** Dermal granulomatous inflammation, epidermal hyperplasia and orthokeratosis (H&E \times 4).

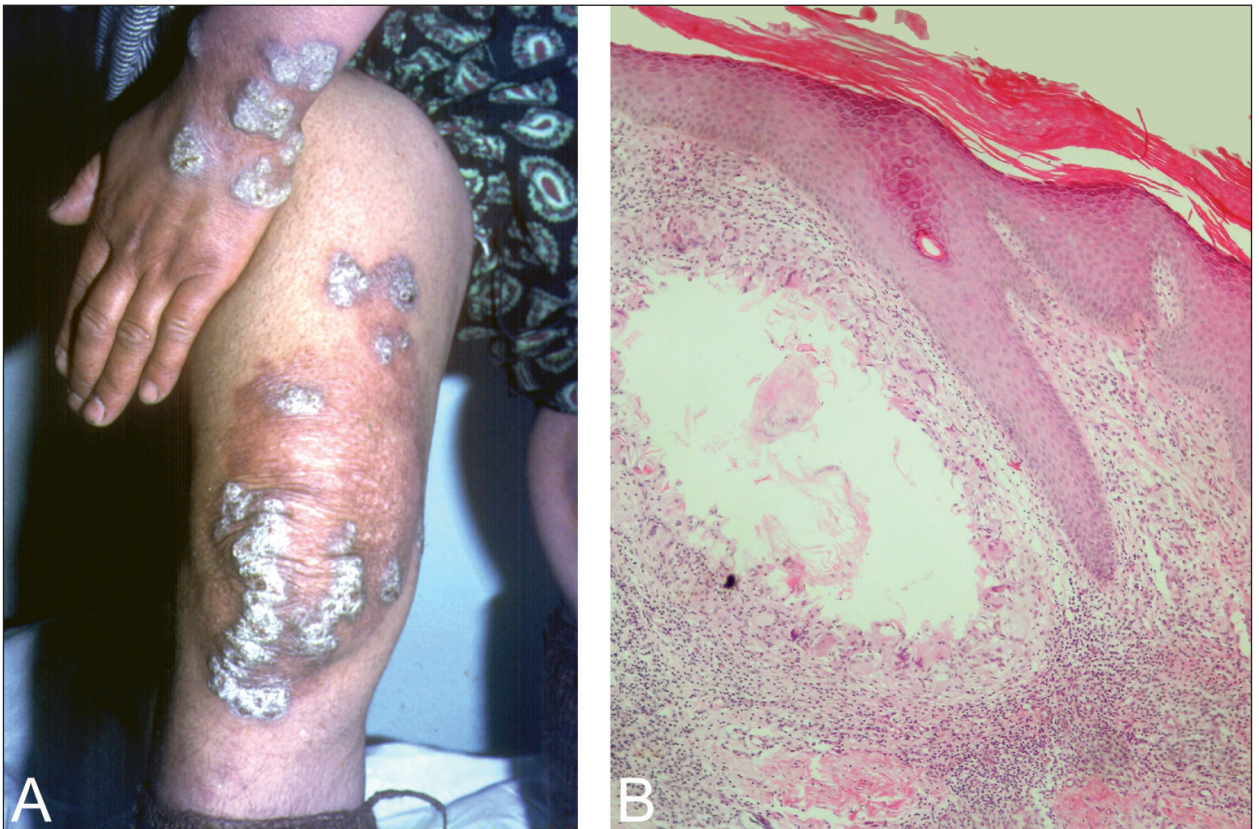


Figure 3A. Verrucous nodules on the left hand, ellipsoid plaque and verrucous nodules on the right knee. **3B.** Non-caseous granulomatous inflammation of the dermis, epidermal hyperplasia, and orthokeratosis (H&E \times 4).

the right buttock after a minor trauma. The lesion was gradually spreaded. No diagnosis had been established and no treatment had been given throughout this long period. Her personal and family histories were not contributory.

Dermatologic examination of the skin surface revealed located, diffuse, well-demarcated, verrucous, large plaques on the gluteal regions (Figure 4A). No BCG scar was visible. An incisional biopsy specimen of the plaques showed a dermal granulomatous inflammation consisting of lymphocytes and epithelioid cells. There was epidermal hyperplasia and orthokeratosis. However, no caseating necrosis was present (Figure 4B). *M. tuberculosis* was cultured from the biopsy specimen after seven weeks.

In all cases, sputum, stool and urine cultures were negative. Laboratory tests showed a normal blood count. VDRL and HIV tests were negative. Fungal and standard bacterial cultures from the skin biopsy were negative. Ziehl-Nielsen and periodic acid-Schiff stains did not demonstrate any acid-fast bacilli. *M. tuberculosis* was cultured from the biopsy specimen except in case 3. Diascopy was negative for apple jelly lesions. There was no lymphadenopathy. The systemic examination was normal. Chest radiography and abdominal ultrasound did not show any pathologic finding. Underlying bone and joint disease was excluded by radionuclide scans.

The clinical features, histopathologic findings, diagnosis, treatment and outcome of the patients of cases 1-4 are shown in (Table 1).

DISCUSSION

The incidence of TBVC varies in different regions and countries of the world. TBVC have been seen more frequently in Asia recently (4). In a recently reported 20-year prospective study 6% of all cases of cutaneous tuberculosis were TBVC (5). Physicians, pathologist and laboratory workers were certain professional groups who had a risk for TBVC, since they might be accidentally infected after contact with tuberculous patients or by autopsy material. In tropical climates, TBVC commonly affects children who contract the bacteria by walking barefoot and sitting on the ground contaminated with tuberculous sputum (2). Although TBVC occurs generally on the hands, the predilection sites for children are the lower extremities (knees, thigh and buttocks) (2). In Europe, TBVC lesions are most encountered on the hands, although

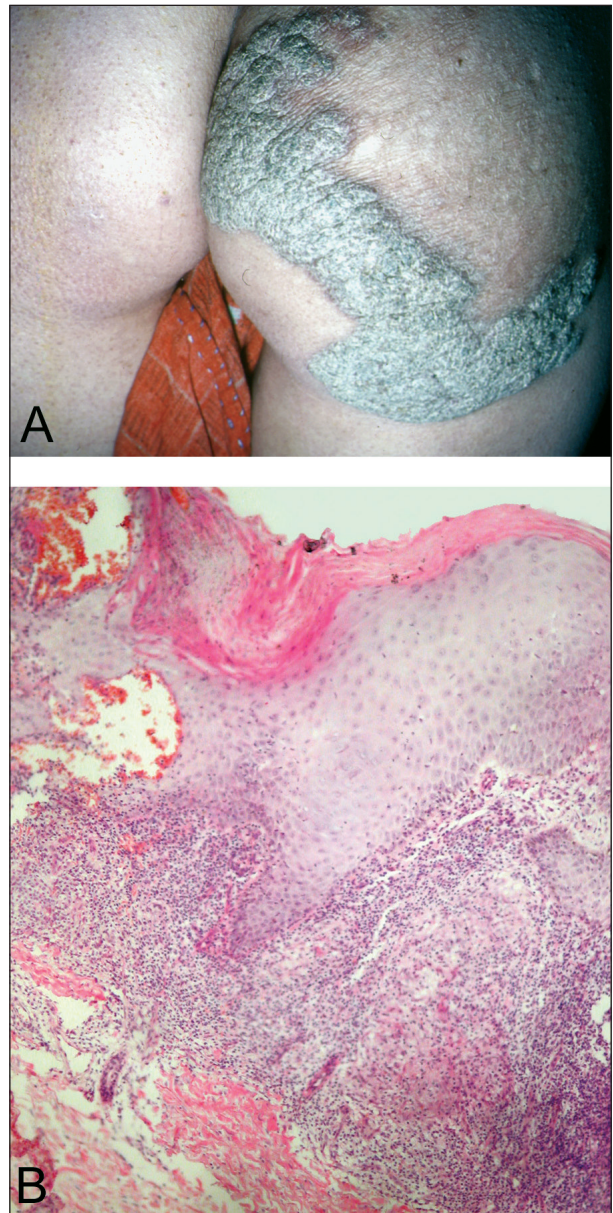

Figure 4A. Well-demarcated, verrucous, large plaques on the gluteal regions. **4B.** Dermal granulomatous inflammation consisting of lymphocytes and epithelioid cells, epidermal hyperplasia, and orthokeratosis (H&Ex4).

the lower limbs and buttocks are the most frequently affected sites in eastern countries (7). In our cases, the lesions were on the hands, lower limbs and gluteal regions. Our patients, excluding the first case, occupied in agriculture and lived in rural regions.

The histopathological features are characterized by marked pseudoepitheliomatous hyperplasia of the epi-

Table 1. The clinical features, histopathologic findings, diagnosis, treatment and outcome of the patients.

Case no	Age	Sex	Area of living	Occupation	Localization	Family history	Duration of disease	Culture result	Tuberculin skin test	Anti-TB therapy	Outcome
1	40	M	Rural area	Farmer	Third finger of the right hand	-	3 years	M. tuberculosis	15 mm/48 hours	pyrazinamide (25 mg/kg/ daily), isoniazid (5 mg/kg/ daily), rifampin (10 mg/kg/ daily) and ethambutol (15 mg/kg/ daily) for two months, followed by dual therapy with isoniazid and rifampin for six months.	Improved
2	45	M	Rural area	Farmer	The right hand	-	5 years	M. tuberculosis	10 mm/48 hours	pyrazinamide (25 mg/kg/ daily), isoniazid (5 mg/kg/daily), rifampin (10 mg/kg/ daily) and ethambutol (15 mg/kg/ daily) for two months, followed by dual therapy with isoniazid and rifampin for six months.	Improved
3	55	F	Rural area	Farmer	Right foot and left hand	-	10 years	-	negative	pyrazinamide (25 mg/kg/ daily), isoniazid (5 mg/kg/ daily), rifampin (10 mg/kg/ daily) and ethambutol (15mg/kg/ daily) for two months, followed by dual therapy with isoniazid and rifampin for six months.	Improved
4	32	F	Rural area	Farmer	The right gluteal area	-	9 years	M. tuberculosis	10 mm/48 hours	pyrazinamide (25 mg/kg/ daily), isoniazid (5 mg/kg/ daily), rifampin (10 mg/kg/ daily) and ethambutol (15 mg/kg/ daily) for two months, followed by dual therapy with isoniazid and rifampin for six months.	Improved

dermis with hyperkeratosis and dense inflammatory cell infiltrate consisting of neutrophils, lymphocytes and giant cells. The presence of granulomatous infiltrates is a cardinal sign. Typical tuberculous foci with caseating necrosis are uncommon (2,3). The laboratory diagnosis of paucibacillary forms of cutaneous tuberculosis, like TBVC, is arduous. Culture has low sensitivity in paucibacillary conditions. In addition to this disadvantage; it may also take weeks for obtaining available result, delaying initiation of therapy. In some studies, microscopy and culture are often negative (1). It might be possible to use the dramatic response to antitubercular therapy as a diagnostic criterion (3). Both diagnosis of TBVC and management of clinical response following anti-tuberculosis treatment are mainly based on the clinical appearance, positive culture results, and microscopic features of the lesion (1).

The differential diagnosis must clinically be made by other unusual infections such as blastomycosis, chromomycosis, fixed sporotrichosis, lesions caused by non-bacterial mycobacteria, lupus vulgaris, and tertiary syphilis. Inflammatory dermatoses including psoriasis, lichen simplex chronicus and hypertrophic lichen planus may mimic this clinical picture. Differentiation from inflammatory conditions may be made histologically, but non-bacterial mycobacterium may be more difficult to diagnose and usually needs culture of the causative organism (2,9). These findings allowed us to rule out a deep mycotic infection (cultures for fungi), tertiary syphilis (negative serologic results), and non-bacterial mycobacteriosis (culture results). We made differential diagnosis with lupus vulgaris by means of involvement area (there are face and neck involvement in lupus vulgaris) and histopathology (there was appearance of pseudoepitheliomatous hyperplasia of epidermis).

The BCG vaccination is still regarded as safe and effective. The most common adverse effects, usually as a result of impaired immunity are, infection spreading to lymph nodes, accelerated reaction after vaccination, and ulceration or abscess formation at the site of vaccination (10). The diagnostic value of positive tuberculin skin test is blurred if the subject has a history of BCG vaccination in early life or previous mycobacterial infections. Thus confirmation is not always positive (11). Mantoux test were positive in our three cases; case 1, case 2 and case 4 and was negative in one of our case; case 3. There were BCG scars in case 1 and case 2 and there were

not any scars in case 3 and case 4. The presence of Mantoux test positivity in cases 1 and 2 might be related to BCG vaccination.

In conclusion, TBVC is still a very important health problem in underdeveloped or developing countries. In differential diagnosis TBVC must be considered for the lesions having a verrucous plaque localized on any part of the body.

REFERENCES

1. Foo CC, Tan HH. A case of tuberculosis verrucosa cutis-undiagnosed for 44 years and resulting in fixed-flexion deformity of the arm. *Clin Exp Dermatol* 2005; 30: 149-51.
2. Gruber PC, Whittam LR, du Vivier A. Tuberculosis verrucosa cutis on the sole of the foot. *Clin Exp Dermatol* 2002; 27: 188-91.
3. Sehgal VN, Sardana K, Bajaj P, Bhattacharya SN. Tuberculosis verrucosa cutis: Antitubercular therapy, a well-conceived diagnostic criterion. *Int J Dermatol* 2005; 44: 230-2.
4. Pereira MB, Gomes MK, Pereira F. Tuberculosis verrucosa cutis associated with tuberculous lymphadenitis. *Int J Dermatol* 2000; 39: 856-8.
5. Masellis P, Gasparini G, Caputo R, Alessi E. Tuberculosis verrucosa cutis which remained undiagnosed for forty-three years. *Dermatology* 1995; 191: 145-8.
6. Sehgal VN, Sehgal R, Bajaj P, et al. Tuberculosis verrucosa cutis (TBVC). *J Eur Acad Dermatol Venereol* 2000; 14: 319-21.
7. Iizawa O, Aiba S, Tagami H. Tuberculosis verrucosa cutis in a tumour-like form. *Br J Dermatol* 1991; 125: 79-80.
8. Tan SH, Tan HH, Sun YJ, Goh CL. Clinical utility of polymerase chain reaction in the detection of *Mycobacterium tuberculosis* in different types of cutaneous tuberculosis and tuberculids. *Ann Acad Med Singapore* 2001; 30: 3-10.
9. Chinchilla D, Martorano A, Rodriguez E, Villanueva C. Cutaneous tuberculosis: efficient therapeutic response in a case with multiple lesions. *Cutis* 1999; 64: 49-52.
10. Wozniacka A, Schwartz RA, Sysa-Jedrzejowska A, et al. Lupus vulgaris: Report of two cases. *Int J Dermatol* 2005; 44: 299-301.
11. Bock M, Nolte O, Hartschuh W, Jappe U. Lupus vulgaris in a skin graft.
12. Bock M, Nolte O, Hartschuh W, Jappe U. Lupus vulgaris in a skin graft. *Acta Derm Venereol* 2003; 83: 132-3.