

Urinary System Infection Caused by *Paecilomyces Variotti*

Selcan Çolakoglu¹, Süleyman Durmaz¹, Hakan Poyrazoğlu², F. Filiz Kasap Tekinsen¹, M. Altay Atalay¹, A. Nedret Koc¹

ABSTRACT

Fungal organisms are one of the important factor in nosocomial urinary tract infections caused by endo-urological procedures. Herein we report a case of pyelonephritis caused by *Paecilomyces variotti* in a 14-month-old child following an uriner tract operation. He had operation in 3.5-month-old for reason of ureteropelvic junction obstruction. Approximately two months after the operation a tissue fragments ejected from urinary tract. The patient admitted to our hospital because of bimonthly recurrence was occurred. This tissue fragment was sent for fungal studies to our department. Direct microscopy revealed hyphae. *P. variotti* was isolated from discarded tissue fragments. Cure was achieved by 2 mg / kg / day for 15 days treatment with amphotericin B.

Key words: *Paecilomyces variotti*, Pyelonephritis, Urinary system infection

INTRODUCTION

Paecilomyces species exist extensively in the world as soil saprophyte, insect parasite and biological deterioration factor. Most important species of those that may occur in patient with intact or impaired immune system are cutaneous and subcutaneous infection, pulmonary infection, pyelonephritis, sinusitis, cellulitis, endocarditis and fungemia. Surgical operations, placed prosthesis, using of contaminated solutions or lotions are risk factors that cause infection. Because, conidium of both are partially resistant to the most of sterilization techniques (1). In this case, it is aimed to represent the urinary system infection case which is caused by *P. variotti* that grown after double -J (D-J) catheter insertion owing to ureteropelvic (UP) obstruction.

Erciyes University Faculty of Medicine, Department of Medical Microbiology, Kayseri, Turkey¹ Erciyes University Faculty of Medicine, Department of Pediatrics, Kayseri, Turkey²

Received: 19.10.2014, Accepted: 04.02.2015

Paecilomyces varottii'nin Etken Olduğu Üriner Sistem Enfeksiyonu: Bir Olgu Sunumu

ÖZET

Mantar elemanları girişimsel üriner işlemler nedeniyle nosokomial üriner sistem enfeksiyonlarının önemli bir etkenidir. Burada 14 aylık bir çocukta üriner sistem operasyonu sonrası *Paecilomyces variotti*'nin etken olduğu piyelonefrit olgusunu bildirdik. Hasta 3.5 aylıkken üreteropelvik darlık nedeniyle opere edildi. Operasyondan yaklaşık iki ay sonra üriner sisteminden doku parçası attı. İki ayda bir bu şikayetleri tekrarlayan hasta kliniğimize başvurdu. Hastanın çıkardığı doku parçası mantar açısından değerlendirilmek üzere laboratuvarımıza gönderildi. Direkt mikroskopide hifler izlendi. Doku parçasının kültüründen *P. variotti* izole edildi. 2 mg/kg/gün amfoterisin B ile 15 günde kür sağlandı.

Anahtar kelimeler: *Paecilomyces variotti*, piyelonefrit, üriner sistem enfeksiyonu

CASE

Because of UP obstruction, a double catheter was inserted to 14 months old patient when he was 3.5 months old. D-J catheter was removed one month later of installation. After that, patient discharged urine with tissue fragments painfully once in every 2 months. Patient was admitted our pediatric clinic with these complaints that continued for 10 months. An erythrocyte, 24 leucocytes (x400) but not epithelia cell was seen in urinalysis of patient. In urinary system USG, right kidney was 72x25 mm, left kidney was 95x42 mm in sizes while parenchyma thickness was 8 mm on right and 6 mm on left. Right kidney parenchyma echo had increased (grade1). Stone was viewed in bilateral kidneys. Pelvicaliectasy is viewed and pelvis anteroposterior (AP) diameter was measured

Correspondence: Specialist MD. Suleyman Durmaz
Konya Numune Hospital, Microbiology Laboratory, Konya, Turkey

E-mail: dr_suleyman111@hotmail.com

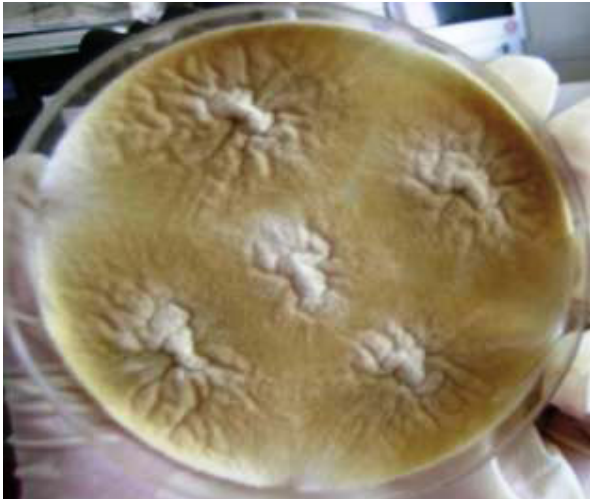

Figure 1. Colony morphology of *P. variotii*

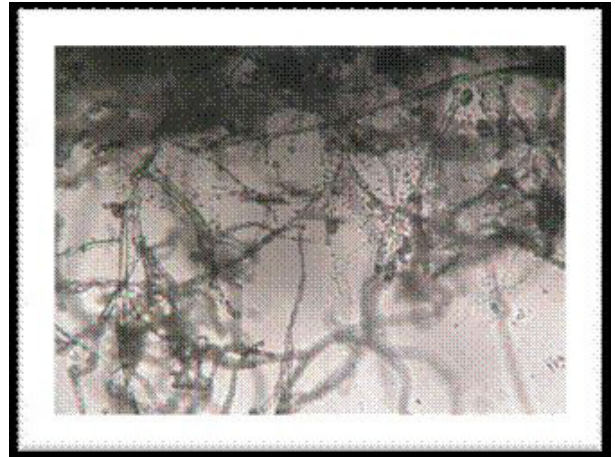


Figure 2. Microscopic appearance of *P. variotii*

6 mm in right kidney. An advanced degree of pelvicaliectasy is viewed and AP diameter was measured as 34 mm. The fragment of tissue from hospitalized and followed-up patient's urinary system was sent to pathology and microbiology laboratory. In cytological examination, neutrophil and urinary system epithelia cell were monitored on proteinoz covered ground. Tissue fragments from patient were macroscopically examined. It was approximately 0.5x0.3 cm. Members of fungi was seen in direct examination of sample which was treated with 15-20% KOH. Inoculation is performed on to Sabouraud dextrose agar (SDA) with antibiotics and cycloheximide and without antibiotics to culture of clinical sample. It is described as *P. variotii* according to macroscopic morphology of fungus and microscopic morphology of slide culture. Macroscopic morphology: Colony had a powdery appearance and was yellowish to brown in color (Figure 1). Microscopic morphology: Conidiophores was uniformly branched, metula with 2-7 phialides and phialides shown an obstructed appearance on edges and long neck-shape was viewed. Conidium of those was viewed ellipsoidal or columnar in shape and yellowish to brown in color with smooth surface. There was single brown conidiums that were located at terminal or middle of hypha (Figure 2). In vitro, antifungal susceptibility of grown fungi was studied with E-test method. Minimal inhibitor concentrations (MIC) of amphotericin B, voriconazole, caspofungin, itraconazole were found as 0.008 µg/mL, 1.5 µg/mL, 16 µg/mL, 0.64 µg/mL, respectively.

DISCUSSION

Fungi in systemic infections, especially saprophytes have been encountered increasingly as an infection agent. It is important to describe the fungus at species level, owing to difference of susceptibility of all. Diagnosis of fungi, especially moulds is based on their macroscopic and microscopic features and must be performed by specialist microbiologists. *Penicillium* spp is confused with *Paecilomyces* spp morphologically. In distinctive diagnosis, be it colonies other than green or blue-green, be it phialides which is wider in basal parts, show obstruction towards to neck-point and be it to leave the main axis by bending, are the most significant morphological properties used to differentiate from *Penicillium* (1). Isolated *P. variotii* strain in this case is described by means of characteristic yellow-brown pigmented appearance and morphology of chain-shaped phialoconidia of single cell which is produced from phialide (2). It has been reported that *P. variotii* was isolated as a disease agent in patients who with intact or impaired immune system (2, 3, 4). Wang et al.(4) have reported a splenic abscess case caused by *P. variotii* in a 21 months old male patient who had chronic granulomatosis disease with impaired immune system. In this case there was not any detected immune defect as well as male and 14 months was similar terms, but an interventional transaction has performed on urinary system. Fungi have been source of nosocomial urinary system infection since the interventional urinary transactions started (2).

First *Paecilomyces* case isolated from genitourinary sys-

Table 1. Minimal inhibitor concentrations of antifungals

Antifungal	MIC
Amphotericin B	0.008 µg/mL
Voriconazole	1.5 µg/mL
Caspofungin	16 µg/mL
Itraconazole	0.64 µg/mL

tem, published by Sherwood et al. (3) at 1983, is an infection case which is occurred after correction of obstructive uropathy. A study published by Sriram et al. (2) 49 years old diabetic patient who had *P. variotii* case occurred after interventional urinary transactions, did not respond to treatment with 200 mg of fluconazole per day for 3 weeks and could be able to treated with 1mg/kg/day for 4 weeks. In the case of *P. variotii* grown after interventional transaction to urinary system, patient healed with 2 mg/kg/day of amphotericin B within 15 days and any problems observed in following months.

Extensive sensivity studies of *P. variotii*, in vivo, are inadequate although studies on sensivity to antifungals. Agulier et al.(5) have indicated that *P. variotii* strains are most susceptible to amphotericin B. Kantarcioglu et al. (6) have indicated that *P. variotii* strains are susceptible to amphotericin B, itraconazole, ketoconazole and 5-flou-rocytosine but resistant to fluconazole and miconazole. In this case lower MIC values were determined for amphotericin B and itraconazole; and higher MIC values for vori-

conazole and caspofungin as a result of in vitro antifungal sensivity study. Fungal infections and, although rare than those, *P. variotii* should be considered as a factor of infections which occurred after interventional transactions in adult patient as well as pediatrics patients. Owing to *P. variotii* strains are able to resist to antifungals, it is necessary to perform antifungal susceptibility tests and treatments should be planned accordingly.

REFERENCES

1. Verweij PE, Brandt ME: *Aspergillus, fusarium, and other opportunistic moniliaceous fungi* In: Patrick R. Murray, Ellen Jo Baron, James H. Jorgensen, Marie Louise Landry, Michael A. Pfaller, Robert H. Yolken, eds. *Manual of Clinical Microbiology*. 9th Ed., Washington D.C., 2007;1802-1838.
2. Sriram K, Mathews MS, Gopalakrishnan G. *Paecilomyces pyelonephritis in a patient with urolithiasis* Indian J Urol. 2007; 23(2): 195-197.
3. Sherwood JA, Dansky AS. *Paecilomyces pyelonephritis complicating nephrolithiasis and review of Paecilomyces infections*. J Urol. 1983;130:526-528.
4. Wang S-M, Shieh C-C, Liu C-C. *Successful treatment of Paecilomyces variotii splenic abscesses: a rare complication in a previously unrecognized chronic granulomatous disease child*. Diagnostic Microbiology and Infectious Disease 2005; 53: 149-152.
5. Aguilar C, Pujol I, Sala J, Guarro J. *Antifungal susceptibilities of Paecilomyces species*. Antimicrob Agents Chemother. 1998; 42: 1601-1604.
6. Kantarcioglu AS, Hatemi G, Yücel A, De Hoog GS, Mandel NM. *Paecilomyces variotii central nervous system infection in a patient with cancer*. Mycoses. 2003; 46: 45-50.